

CARBENDAZIM DISRUPTS SEXUAL MATURITY IN MALE GOATS (*Capra Hircus*)

Waghe Prashantkumar¹, S.P.S Saini², R.S Sethi³, S.P.S Ghuman⁴,
S. Rampal², N. Prakash¹ and L.V Lokesh¹

¹Department of Veterinary Pharmacology and Toxicology, Veterinary College, Shivamogga 577 204 (India).

²Department of Veterinary Pharmacology and Toxicology, College of Veterinary Sciences, GADVASU, Ludhiana 141004, Punjab (India).

³School of Animal Biotechnology, College of Veterinary Sciences, GADVASU, Ludhiana 141004, Punjab (India).

⁴Department of Animal Reproduction, Gynaecology and Obstetrics, College of Veterinary Sciences, GADVASU, Ludhiana 141004, Punjab (India).

*Corresponding Author Email: drprashant1985@gmail.com

ABSTRACT

The present investigation reports the effect of repeated administration of carbendazim on the sexual maturity of male goats. Goats in the treatment group (n=7) were administered carbendazim orally once daily @ 50 mg/kg body weight/day for 90 consecutive days. After 90 days of administration, there was no increase in testosterone levels in treatment group animals, in contrast to control group animals (n=7) which had significantly increased testosterone levels due to achieving of sexual maturity. Histologically, testes of intoxicated goats had a complete disorganization of spermatogenic cell rows with little affect on leydig cells. From the present investigation, it can be concluded that subchronic exposure of carbendazim disrupts the sexual maturity in male goats. Further studies are needed to pinpoint the exact mechanism and location of this disruption at hypothalamic-pituitary-testes level.

KEYWORDS

Male Goats, Carbendazim, Testosterone, Subchronic.

INTRODUCTION

In the present world scenario, pesticides have become an indispensable tool for the sustenance of mankind through crop protection and control of various pests. Carbendazim (methyl-2-benzimidazole carbamate; MBC) is used as a pesticide, herbicide in horticulture and agriculture, preservative in paint, textile, papermaking and leather industry as well as a preservative for fruits^{9,27}. It is currently one of the most widely used, broad spectrum fungicides to protect them from decay caused by various fungal pathogens. The fungicidal property of carbendazim is targeted towards tubulin, causing disruption of microtubule formation and mitotic cell division^{5,6,10}.

Man could be exposed to carbendazim either through environmental contamination or

occupational exposures. Occupational exposure to carbendazim is known to cause various ailments including vomiting, irritation in eyes, nose and throat, hypertension, rapid pulse, headache and blurred vision. Carbendazim has been demonstrated to be the active toxicant responsible for the testicular toxicity in rats^{3,8}. Further, carbendazim and its metabolite benomyl have been known to induce testicular toxicity, characterised by sloughing of immature spermatids¹⁴ and the inhibition of microtubule assembly¹⁷.

Several other studies conducted in rats^{2,18,26}, mice⁸, hamsters¹² and Japanese quails¹ have elaborated the seriousness of carbendazim and benomyl toxicity towards reproductive system. But till date no study has been done on endocrine disruption abilities of carbendazim (one of the

most commonly used pesticides in India) in goats, a species which is primarily a herd animal in India grazing on the highly contaminated agricultural leftover in fields. This is important as goat is an important food animal for humans, its meat being relished by people from almost all cultural backgrounds. Keeping these facts in mind the present investigation was designed to study the endocrine disruption potential of carbendazim with reference to testosterone cyclicity in male goats.

MATERIALS AND METHODS

EXPERIMENTAL ANIMALS

The experiments were approved and conducted under the institutional guidelines of the Guru Angad Dev Veterinary and Animal Sciences University, Ludhiana, Punjab, India. Fourteen (8 months age, 12-15 kg body weight) Amritsari male goats were used in the present study. This age group was selected since we wanted to conduct experiments during the period of attainment of sexual maturity (which is around 11 months of age for *Capra hircus*). The animals were acclimatized in the animal shed of department under uniform conditions for 3 weeks before the start of experiment. During this period all animals were subjected to regular clinical examination and treated with anthelmintics for deworming. The animals were maintained on green fodder and wheat straw and water was provided ad libitum. Carbendazim fungicide (Bavistin 50% WP) formulation was purchased from BASF India Ltd. (Mumbai, India). Goats were randomly divided in to two groups, control and treatment (N= 7, each). To the animals of the treatment group, carbendazim dissolved in water and administered by gavage, at daily dose of 50 mg per kg body weight, for 90 consecutive days. All the experimental animals were kept under close observation for period of 120 days. Goats treated with carbendazim were closely observed for appearance of symptoms of toxicity. The nature,

degree, and time of occurrence of various symptoms were recorded during the experimental period.

Sampling schedule

At beginning and end of study i.e. 0 day and 90th day, blood samples were collected from both groups of goats at the regular intervals of 20 minutes over a period of 6 hour in heparinized vials for studying testosterone cyclicity. After the carbendazim treatment period was over i.e. on 91st day, the goats of both groups were injected GnRH analogue buserelin acetate injection as a single iv dose (0.0042 mg). After the GnRH injection, blood samples were collected at 20 minutes intervals over a period of 90 minutes in heparinised vials to study its potential for inducing testosterone levels. Plasma was separated by centrifugation of blood samples at 3000 g for 15 min and stored at -20 °C till analysis, usually on the next day.

ASSAY PROCEDURES

Testosterone: Testosterone kits purchased from Monobind Inc Lake Forest, CA, USA. To determine the concentration of testosterone for an unknown, the absorbance for each duplicate serum reference versus the corresponding testosterone concentration (0, 0.1, 0.5, 1.0, 2.5, 5.0, 12.0 ng/ml) were plotted and the slope was drawn with least square regression analysis.

Histological studies

Testes were removed from control and experimental animals surgically on 92nd day and fixed in 10% neutral buffered formalin. The tissue samples were processed to get 5 µm thick paraffin sections which were stained with haematoxylin and eosin.

Statistical analysis

The statistical analysis was done by Student's T-test.

RESULTS AND DISCUSSION

Carbendazim at the dose rate of 50 mg/kg/day for 90 consecutive days did not produce any apparent signs of toxicity. The levels of testosterone in control and treatment groups are shown in **Table 1, 2 and Fig. 1, 2**. The levels of testosterone were significantly increased on day 90 as compared to day 0 in control group. In contrast, in the

treatment group, the testosterone levels were almost similar on day 0 and 90, showing that carbendazim did not allow maturation of testes in these animals. Significant decrease in cumulative testosterone amount over 6 hr period in goats exposed to carbendazim, compared to untreated goats, was observed.

Table 1: Effect of repeated oral administration of carbendazim (50 mg/kg body weight/day) on the testosterone cyclicity in male goats.

| Time (Min) | Groups (Control) | | | Groups (Treatment) | | |
|------------|------------------|----------------------|---------------------------|--------------------|----------------------|---------------------------|
| | 0 Day | 90 th Day | 90 th Day GnRH | 0 Day | 90 th Day | 90 th Day GnRH |
| 0 | 0.87±0.30 | 2.76±0.56* | 2.66±0.43 | 1.59±0.21 | 1.70±0.24 | 1.39±0.29 |
| 20 | 1.09±0.28 | 3.14±0.47* | 2.83±0.29 | 1.46±0.17 | 1.26±0.17 | 1.65±0.37* |
| 40 | 1.33±0.20 | 2.94±0.55* | 3.42±0.34 | 1.43±0.18 | 1.46±0.36 | 4.63±0.53 |
| 60 | 0.91±0.36 | 3.42±0.56** | 3.78±0.49 | 1.54±0.28 | 1.80±0.31 | 5.99±0.45 |
| 80 | 1.21±0.28 | 3.87±0.42* | 4.74±0.47 | 1.73±0.13 | 1.64±0.37 | 6.55±0.52 |
| 100 | 0.81±0.21 | 4.20±0.61** | 5.21±0.39 | 1.64±0.26 | 1.59±0.34 | 6.38±0.62 |
| 120 | 0.91±0.20 | 3.02±0.59** | | 1.43±0.21 | 1.70±0.20 | |
| 140 | 1.05±0.35 | 3.36±0.62** | | 1.56±0.37 | 1.81±0.42 | |
| 160 | 0.99±0.22 | 3.90±0.65** | | 1.24±0.27 | 1.06±0.32 | |
| 180 | 0.97±0.19 | 3.65±0.69** | | 1.45±0.36 | 1.77±0.60 | |
| 200 | 0.65±0.24 | 3.89±0.67** | | 1.36±0.36 | 2.12±0.34 | |
| 220 | 0.60±0.24 | 4.37±0.47** | | 0.94±0.37 | 1.82±0.35 | |
| 240 | 0.52±0.23 | 3.80±0.51** | | 1.09±0.30 | 1.43±0.32 | |
| 260 | 0.49±0.19 | 4.55±0.65** | | 1.22±0.32 | 1.47±0.33 | |
| 280 | 0.63±0.22 | 3.51±0.66** | | 1.35±0.33 | 1.80±0.38 | |
| 300 | 0.59±0.17 | 4.13±0.62** | | 1.20±0.30 | 1.77±0.46 | |
| 320 | 0.57±0.22 | 4.34±0.46** | | 1.20±0.27 | 1.70±0.40 | |
| 340 | 0.72±0.23 | 5.10±0.45** | | 1.37±0.33 | 2.34±0.64 | |
| 360 | 0.89±0.23 | 3.72±0.54** | | 1.69±0.34 | 2.08±0.35 | |

All the values expressed as Mean ± S.E (n = 7)

Test of significance by student 't' test * P<0.05 ** P<0.01

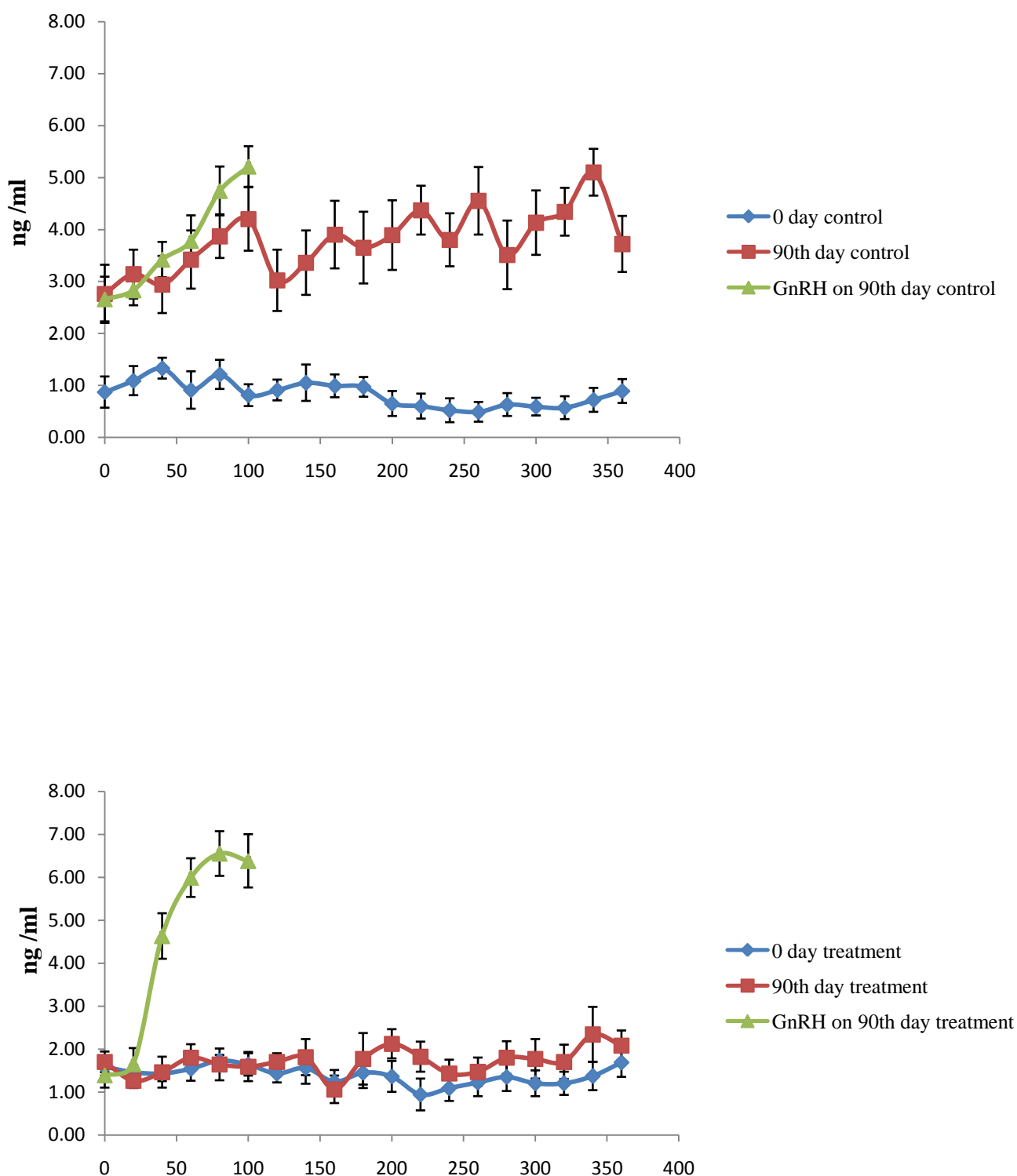


Fig. 1: Effect of carbendazim administration on testosterone cyclicity in male goats (n=7 for both the groups).

Table 2: Cumulative concentration of testosterone secreted in 6 hours in control group and carbendazim treated group.

| Group I (Control) | | Group II (Treatment) | |
|-------------------|----------------------|----------------------|----------------------|
| 0 Day | 90 th Day | 0 Day | 90 th Day |
| 15.8±0.06 | 71.7±0.14* | 26.5±0.05 | 32.3±0.07 |

All the values expressed as Mean ± S.E (n = 7)
Test of significance by student 't' test * P<0.05 ** P<0.01

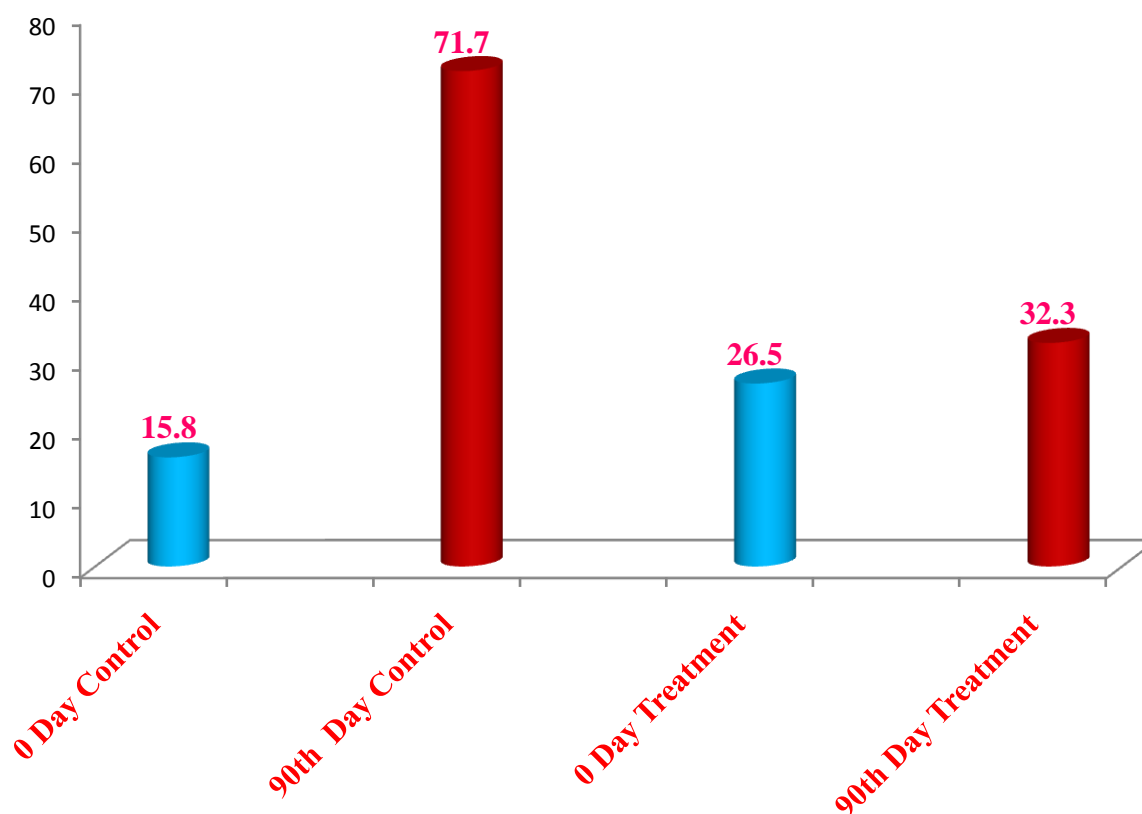


Fig. 2: Cumulative concentration of testosterone in control group and carbendazim treated group (n=7 for both the groups).

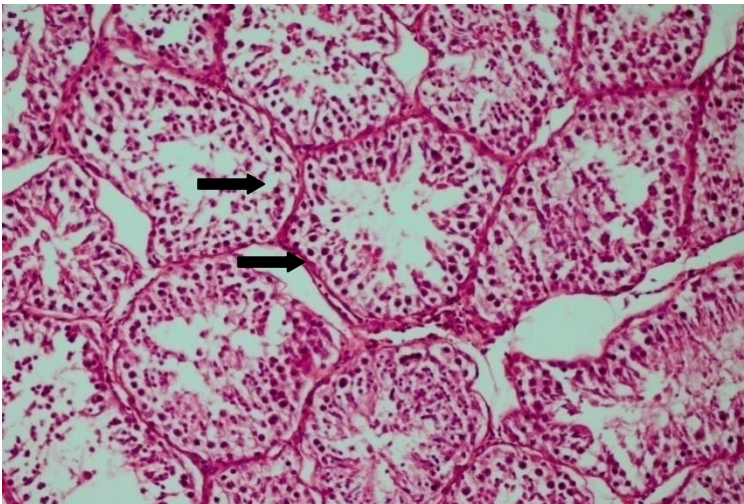


Fig. 3: Normal histology of Testis. HE 20X

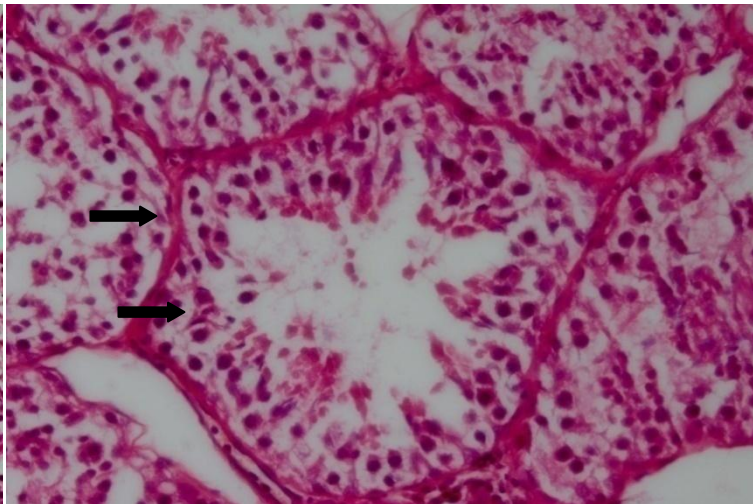


Fig. 4: Normal histology of Testis. HE 40X

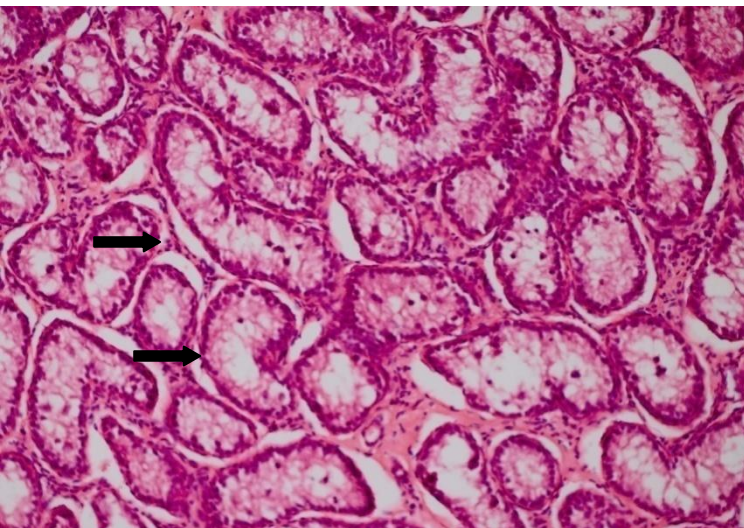


Fig. 5: Disruption of seminiferous tubules with sloughing of germinal epithelium layer and marked disorganization of spermatogenic cell rows. HE 20X

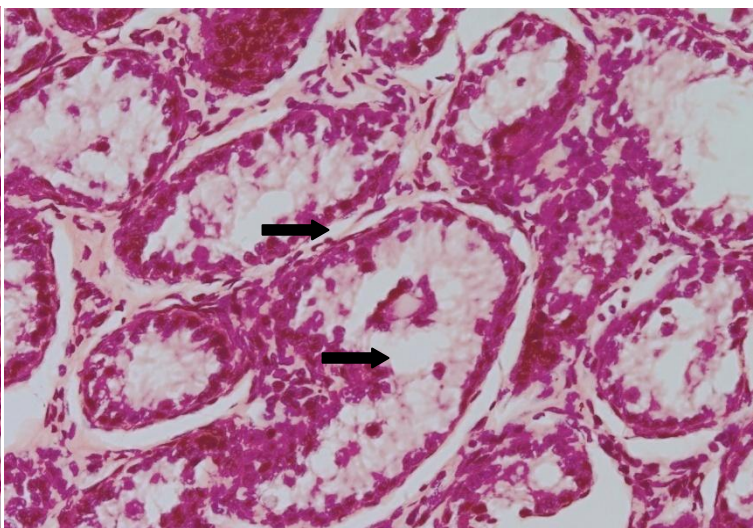


Fig. 6: Disruption of seminiferous tubules with sloughing germinal epithelium layer and marked disorganization of spermatogenic cell rows, few multinucleated giant cell and few leydig cells showed pyknotic appearance. HE 40X

Normally, in males, hypothalamus secretes GnRH (Gonadotropin Releasing Hormone) which acts on anterior pituitary to secrete ICSH (interstitial cell stimulating hormone) and LH (luteinizing hormone). ICSH and LH become blood borne acting ultimately on testes. ICSH stimulates immature germ cells to produce spermatogenic cell rows and increase spermatogenesis. In addition, ICSH increases sertoli cell synthesis of an androgen binding protein (ABP) required for maintenance of high concentration of testosterone. LH stimulates testosterone production by the leydig cells of the testis ¹⁵. Carbendazim may indirectly suppress the secretion of the gonadotropin. Therefore, hormonal imbalance might occur due to impairment of either synthesis or secretion ²². Carbendazim acts on the hypothalamic-pituitary endocrine axis indirectly through effect on the sertoli cell ¹¹.

In present study, there was a significant decrease in testosterone level in carbendazim treated group as compared to control group. Also, there was sloughing of germinal epithelial layer and disorganization of spermatogenic cell rows. The present investigation is in tune with findings of other researcher ² who reported a significant decrease in total serum testosterone level in rats exposed to carbendazim. To elucidate mechanism of toxicity ²⁰ showed that stage specificity of the sloughing is due to stage-specific susceptibility of the sertoli cell microtubules to carbendazim.

To see at what level carbendazim is having its affect, we injected GnRH in both groups of animals at the end of treatment period (91st day). GnRH increased the testosterone levels in carbendazim treated group, almost equal to the levels attained in untreated group. This clearly shows that that carbendazim is acting either at the hypothalamus level (affecting the production / release of GnRH from there) or at the anterior pituitary level (affecting ICSH production or release). Since testosterone is being increased in

treated group within a very short time after GnRH injection, it means that testosterone was already produced by Leydig cells (i.e LH signal was present which means the GnRH signal was also present although may be to a low level), but it was either not being released into the circulation or the ABP required for maintenance of its high concentration was lacking in the treated goats. Since the synthesis of ABP required for maintenance of high concentration of testosterone is dependent on ICSH stimulation, this could implicate decreased ICSH levels also. In carbendazim treated animals, the integrity of spermatogenic rows is clearly disrupted which is again dependent upon the ICSH stimulation. So, most probably, carbendazim is affecting ICSH producing cells of anterior pituitary leading to less ICSH production and decrease in synthesis of ABP and spermatozoa. However, further studies are needed to to measure ICSH concentration in carbendazim treated animals. At the same time it can be speculated that LH producing cells in anterior pituitary are not being affected (since the testosterone concentration suddenly increases after GnRH injection. But it is very difficult to say clearly at present how much is the contribution of low ICSH or GnRH levels towards the overall affect of carbendazim. Similar observations have been recorded by ²⁹. Who reported that carbendazim exposure had no effect on serum LH and prolactin; however it significantly decreased serum testosterone and estradiol levels. In contrast, in other study reported that carbendazim treated male rats had decreased levels of LH as compared to control group but there were no obvious effects on the levels of FSH levels ³⁰.

Other studies have shown no clear cut results. Chronic administration of carbendazim to male rats elevates serum LH / FSH levels and caused changes in human chorionic gonadotrophins (HCG) stimulated testosterone synthesis ¹¹. They were of the opinion that the infertility produced by carbendazim was due to a direct toxic effect of

the insecticide on testicular function. In contrast to findings of the present study, levels of the testosterone were not significantly decreased by carbendazim in male rats^{12, 26}. It has also been reported that sub-chronic exposure to benomyl caused a significant decrease in relative testicular weight and lowered the male fertility index, but did not in alter testosterone, LH or FSH levels⁴. The difference in results obtained by different authors may be attributed to the difference in exposure times to the pesticide.

Testes of normal control goats stained by haematoxylin-eosin stain (**Fig. 3 and 4**) appeared to be formed of seminiferous tubules surrounded by tunica albuginea. Each tubule is surrounded by an outer flattened advential cells and an inner basement membrane. In between the tubules the interstitial connective tissue showed fibroblasts, blood vessels, and Leydig cells. The seminiferous tubules appeared uniform in size and shape. They were lined by regularly arranged rows of spermatogenic cells in different stages of maturation.

Administration of carbendazim at the dose rate of 50 mg/kg for 90 days showed effects on testicular histology (**Figures 5 and 6**). There were disruption of the seminiferous tubules and vacuolisation in the germinal epithelium. Few multinucleated giant cells and proliferation of spermatogonia up to certain level were observed but differentiation of the spermatid and spermatogonia was lacking. Few Leydig cells also showed pyknotic appearance.

Sloughing of immature germ cells and the inhibition of cell division are the first testicular alterations observed after exposure to benzimidazoles in rats¹³. Atrophied seminiferous tubules, vacuolisation of the germinal epithelium, sloughing of germinal epithelium and sertoli cells, fibrosis in interstitial cells findings of the present study are consistent with the findings of others^{3, 18, 20, 25, 29}. The severity of damage increased with the concentration of carbendazim at the target

site, the testis, and also with time after administration^{16, 17}. The fungicidal property of carbendazim is targeted toward tubulin, causing disruption of microtubule formation and mitotic cell division¹⁰. Our histopathological observation are also supported by the observations of other researchers²⁰. Who found that the administration of carbendazim at moderate to low dosage induced sloughing of germ cells and abnormal development of the head of elongating spermatids.

At the molecular level, benzimidazoles bind to the tubulin subunit of the α and β tubulin heterodimer, inhibiting microtubule polymerization²³. Age-dependent differences susceptibility to benomyl induced testicular damage has been reported in following sub-chronic exposure of benomyl by oral route in rats⁷. Rat testis showing mild hypertrophy of the cells of seminiferous tubule and sclerosis and following administration of Carbendazim¹⁹. In the present study, the pathological changes observed in the Leydig cells might be due to increased oxidative stress in testicular Leydig and seminiferous tubules²⁴.

CONCLUSION

From the results of present investigation, it can be concluded that subchronic exposure of carbendazim to male goats decreases the testosterone levels. This may be due alteration in GnRH synthesis in hypothalamus or may be due to decreased synthesis / secretion of testosterone from the leydig cells. Since goats mostly graze on the highly contaminated agricultural leftover in fields in countries like India, public health education is needed to raise general awareness about hazards of irrational use of carbendazim. Also further research is needed in goats to study the tissue residue levels of this very commonly used and "silently sterilizing" pesticide.

REFERENCES

1. Aire, T.A. Short term effects of carbendazim on the gross and microscopic features of the testes of Japanese quails (*Coturnix coturnix japonica*). *Anat. Embryol.*, 210:43-49, (2005)
2. Barlas, N., Selmanoglu, G., Songur, S., Kockaya, E.A., and Erdemli, E. Biochemical and histopathological effect of carbendazim to rat male reproduction. *Pesticide* 17: 59-71, (2002).
3. Barlas, N., Selmanoglu, G., Kockaya, A., Songur, S. Effects of carbendazim on rat thyroid, parathyroid, pituitary and adrenal glands and their hormones. *Hum. Exp. Toxicol.* 21:217-221, (2002)
4. Barnes, T.B., Verlangier, A.J., and Wilson, M.C. Reproductive toxicity of Methyl-1-(Butylcarbomoyl)-2-benzimidazole carbamate (Benomyl) in male wistar rats. *Toxicol.* 28:103-115, (1983)
5. Burland, T.G., and K. Gull. Molecular and cellular aspects of the interaction of benzimidazole fungicides with tubulin and microtubules. In *Mode of action of antifungal agents*, eds. A.P.J. Trinci and J.F. Riley, 299-320. Cambridge, UK: Cambridge Press (1984).
6. Can, A., and Albertini D.F. Stage specific effects of carbendazim (MBC) on meiotic cell cycle progression in mouse oocyte. *Mole Reprod Develop.* 46: 351-362, (1997).
7. Carter, S.D., Hein, J.F., Rehnberg, G.L., and Laskey, J.W. Effect of benomyl on reproductive development of male rats. *J Toxicol Envir Health.* 13: 53-68, (1984).
8. Correa, L.M., Nakai, M., Strandgaard, C.S., Hess, R.A., and Miller, M.G. Microtubules of the mouse testis exhibit differential sensitivity to the microtubule disruptors carbendazim and colchicines. *Toxicol Sci.* 69: 175-182, (2002).
9. Davidse L C. Bendazimidazole fundicide: mechanism of action and biologic impact. *Annu review of phytopatho.* 24: 43-65, (1986).
10. Foster, K.E., Burland, T.G., and Gull, K.A. Mutant beta-tubulin confers resistance to the action of bendazimidazole carbamate microtubules inhibitors both in vivo and vitro. *J Biochem.* 163: 449-455, (1987).
11. Goldman, J.D., Rehnberg, G.L., Cooper, R.L., Gray, L.E.Jr., Hein, J.F., and McElroy, W.K. Effects of the benomyl metabolite, carbendazim, on the hypothalamic-pituitary reproductive axis in the male rat. *Toxicol.* 57, 173-182, (1989).
12. Gray, L.E., Ostby, J.J., Linder, R., Goldman, J., Rehnberg, G., and Cooper, R. Carbendazim induces alteration of the reproductive development and function in the rat and hamster. *Funda Appli Toxicol.* 15: 281-297, (1990).
13. Hess, R.A., and Nakai, M. Histopathology of the male reproductive system induced by the fungicide benomyl. *Histo Histopatho.* 15: 207-224, (2000).
14. Hess, R.A., B. Moore, R.E. Forrer Linder, and A.A. Abuel-Atta. The fungicide benomyl [methyl 1-(butylcarbomoyl)-2-benzimidazole carbamate] causes testicular dysfunction by inducing the sloughing of germ cells and occlusion of efferent ductules. *Funda Appli Toxicol.* 17: 733-745, (1991).
15. Kackar, R., Srivastava, M K., and Raizada R. B. Induction of gonadal toxicity to male rats after chronic exposure to mancozeb. *Ind. Health.* 35: 104-111, (1997).
16. Lim, J., and Miller, M.G. The role of the benomyl metabolite carbendazim in benomylinduced testicular toxicity. *Toxicol Appli Pharmacol.* 142: 401-410, (1997).
17. Lim, J., and Miller, M.G. Role of testis exposure levels in the insensitivity of prepubertal rats to carbendazim-induced testicular toxicity. *Funda Appli Toxicol.* 37: 158-167, (1997).
18. Mahgoub, A.A., and El-Madany, A.H. Evaluation of subchronic exposure of the male rats reproductive system to the insecticide methomyl. *Saudi J Biologic Sci.* 7: 138-145, (2000).
19. Muthuviveganandave V., Muthuraman, P., InHo Hwang and Sri Kumar, K. Biochemical and histological changes induced by low dose of carbendazim on testis of male albino rat. *Int J Pharma Bio Sci*, 1 (4): 572-576, (2011).
20. Nakai, M., and Hess, R.A. Morphological changes in the rat sertoli cell induced by the microtubule poison carbendazim. *Tissue and Cell.* 26: 917-927, (1994).
21. Nakai, M., Miller, M.G., Carnes, K., Hess, R.A. Stage-specific effects of the fungicide carbendazim on Sertoli cell microtubules in rat testis. *Tissue and cell.* 34: 73-80, (2002).
22. Ozemen, G., and Akay, M.T. The effect of malathion on some hormones levels and tissues secreting hormone in rats. *Vet. Toxicol.* 35: 22-24, (1993).
23. Quinlan, R.A., Pogson, C.I., and Gull, K. The influence of the microtubule inhibitor, methyl benzimidazol-2-yl-carbamate (MBC) on nuclear division and the cell cycle in *Saccharomyces cerevisiae*. *J Cell Sci.* 46: 341-352, (1980).
24. Rajeswary, S. B., Kumaran, B., Ilangoan, R., Yuvaraj, S., Sridhar, M., Venkataraman, P., Srinivasan, N., and Aruldas, M.M. Modulation of antioxidant defense system by the environmental fungicide carbendazim in Leydig cells of rats. *Reprod Toxicol.* 24: 371-380, (2007).
25. Rajeswary, S., Mathew, N., Akbarsha, M.A., Kalyanasundram, M., and Kumaran, B. Protective effect of vitamin E against carbendazim-induced testicular toxicity-histopathological evidences and reduced residue levels in testis and serum. *Archi Toxicol.* 81: 813-821, (2007).
26. Rehnberg, G.L., Cooper, R.L., Goldman, J.M., Gray, L.E., Hein, J.F., and McElroy, W.K. Serum and testicular testosterone and androgen binding protein profiles

- following subchronic treatment with carbendazim. *Toxicol Appl Pharmacol.* 101: 55–61, (1989).
27. Selmanoglu, G., Barlas, N., Songer, S., and Kockaya, E.A. Carbendazim induced haematological, biochemical and histopathological changes in liver and kidney of male rats. *Human Exp Toxicol.* 20: 625–630, (2001).
 28. Sivasankaran Rajeswary., Nisha Mathew., Mohammad Abdulkader Akbarsha., Muthuswamy Kalyanasundram., Bassouvalingam Kumaran. Protective effect of vitamin E against carbendazim-induced testicular toxicity-histopathological evidences and reduced residue levels in testis and serum. *Arch. Toxicol.* 81: 813-821, (2007).
 29. Sivasankaran, R., Bassouvalingam, K., Ramachandran, L., Sambandam, Y., Muthusami, S., Prabhu V, Narasimhan, S., and Maria, M.A. Modulation of antioxidant defense system by the environmental fungicide carbendazim in Leydig cells of rats. *Reprod. Toxicol.* 24: 371-380, (2007)
 30. Yu, G., Guo, Q., Xie, L., Liu, Y., and Wang, X. Effects of subchronic exposure to carbendazim on spermatogenesis and fertility in male rats. *Toxicol. Ind. Health.* 25: 41-47, (2009).



***Corresponding Author:**

Dr. Prashantkumar Waghe

Assistant Professor

Department of Pharmacology & Toxicology

Veterinary College, Vinobanagar,

Shivamogga - 577 204, Karnataka (India).

Email: drprashant1985@gmail.com