

ANTIUROLITHIATIC ACTIVITY OF THE PLANT EXTRACTS OF *SOLANUM VIRGINIANUM* ON ETHYLENE GLYCOL INDUCED UROLITHIASIS IN RATS

Krishna Mohan Chinnala*, Srinivas Shanigarm, Madhan Mohan Elsani

Department of Pharmacology, St. John College of Pharmacy, Yellapur,
Hasanparthy, Warangal- 506 371. Andhra Pradesh, INDIA.

*Corresponding Author Email: drchinnala@gmail.com

ABSTRACT

Objective: To study the antiurolithiatic activity of *Solanum virginianum* (Solanaceae) in ethylene glycol induced urolithiasis in male Spargue Dawley rats.

Methods: The urolithiasis was induced in rats by oral feeding of ethylene glycolated water (0.75%v/v) for 28 days. Ethanolic extract of *Solanum virginianum* (200 mg/kg, 400 mg/kg) was administered orally from 1st day for preventive regimen and from 15th day for curative regimen. **Results:** It was observed that the inducing agent ethylene glycol elevated the ionic parameters, calcium and phosphate levels in urine, blood urea nitrogen (BUN), serum creatinine and serum uric acid levels. Treatment with ethanolic extract of *Solanum virginianum* significantly ($P < 0.001$) reduced the elevated levels of ions in urine as well as BUN, serum creatinine and serum uric acid levels.

Conclusion: The elevated calcium and phosphate levels in urine, serum creatinine, blood urea nitrogen (BUN) and uric acid levels of urolithiasis induced rats were reduced with preventive and curative regimens of plant extract treatment. The histological findings also showed improvement in kidney architecture after treatment with the plant extract. These observations enable us to conclude that the *Solanum virginianum* has curative and preventive properties for ethylene glycol induced urolithiasis in rats.

KEY WORDS

Urolithiasis, Ethylene glycol, *Solanum virginianum*, Hyperoxaluria, Micro crystals.

INTRODUCTION

Urolithiasis is a complex process which is a consequence of an imbalance between promoters and inhibitors in the kidneys¹. Even after the technological developments in the present medical practice, the formation and growth of renal calculi continues to afflict humankind. Though various kinds of stones have been identified, calcium stones are the most common in human as well as in rats². Urolithiasis is a common disorder estimated to occur in approximately 12% of the world population, with a recurrence rate of 70-81% in males and 47-60% in females³. The recurrence of urolithiasis represents a

major problem as patients who have formed one stone are more likely to form another.

The synthetic drugs used to prevent urolithiasis are not effective in all patients, and many of them have adverse effects that compromise their long term use. In the present day management of urolithiasis with open renal surgery is an unusual and rarely used one since the introduction of Extracorporeal Shock Wave Lithotripsy (ESWL) which has almost become the standard procedure for eliminating kidney stones⁴. However, in addition to the traumatic effect of shockwaves, persistent residue stone fragments and the possibility of infection suggests that ESWL may cause acute renal injury, a decrease in renal function

and an increase in stone recurrence⁴. Hence, the search for effective antilithiatic drugs without or minimum side effects from natural sources has gained a great potential.

Solanum virginianum is a very prickly perennial herb with woody base plant from the family Solanaceae which is common throughout India, Sri Lanka, Burma, Malaysia and Nepal. The plant is used in rheumatism, asthma, also as diuretic, anthelmintic and anti-inflammatory substance. The aerial parts and the roots are used in herbal preparations. *S. virginianum* is endowed with various chemical components such as alkaloids, flavonoids, phytosterols, mucilage and fixed oil etc., which possibly contribute to its vast uses in folklore medicine⁵. The present study was planned to evaluate the antiurolithiatic activity of ethanolic extract of *Solanum virginianum* whole plant on ethylene glycol induced calcium oxalate urolithiasis in male rats.

MATERIALS AND METHODS

Plant material

The plants of *Solanum virginianum* were collected from surroundings of Warangal, Andhra Pradesh, India and the plant was authenticated by plant taxonomist Prof. D.V.S.Raju., Department of Botany and Plant anatomy research center, Kakatiya University, Warangal, Andhra Pradesh. The voucher specimen of the plant was deposited at the college for the future reference.

Preparation of ethanolic extract

The whole plants of *Solanum virginianum* were cleaned and chopped into small pieces and dried under shade. The coarse powder was obtained by mechanical grinding. The powdered material (100 g) was subjected to continue hot extraction in soxhlet apparatus at a temperature of (60- 70^o C) by using ethanol (95% v/v) as solvent⁶. After complete extraction, the extract was dried. The yield was about 5% w/w and it was stored at 4^oC in desiccator. The extract was suspended in distilled water using 1% acacia as suspending agent for oral administration to animals.

Experimental animals

The Spargue dawley rats, weighing 150-200g, were procured from Teen baobabs Pvt. Ltd. (Rag, no.

177/99 CPCSEA), Hyderabad, Andhra Pradesh. And they were housed at CPCSEA (Rag, no. 1278/ac/09/cpcsea) approved animal house of St. John College of Pharmacy, Warangal. The animals were kept in polypropylene cages (6 in each cage) under standard laboratory condition (12 hr light and 12 hr dark cycle) and had free access to commercial pellet diet (Hindustan lever L.td, Bombay, India) with water *ad libium*. The animal house temperature was maintained at 25 ± 2^oC with relative humidity at (50 ±15%). Ethical norms were strictly followed during all experiments and the study was approved by the Institutional Animal Ethical Committee of St. John College of Pharmacy (Reference No: 001/IAEC/StJCOP/2011).

Acute Toxicity Study

The acute toxicity of ethanolic extract of *Solanum virginianum* was determined as per the OECD guideline no.423 (Acute Toxic Class Method). It was observed that the test extract was mortal even at 2000mg/kg dose. Hence, 1/10th (200mg/kg) and 1/5th (400mg/kg) of this dose were taken as a therapeutic dose for determination of antiurolithiatic effect⁷.

Pharmacological screening for anti urolithiatic activity

Animals were divided into seven groups, each containing six animals. Group I animals served as normal control and maintained on regular laboratory diet and water *ad libium*. Group II to VII animals were fed with 0.75% ethylene glycol (EG) in water to induce renal calculi till 28th day⁸. Group III animals received standard antiurolithiatic drug cystone[®] (750 mg/kg body weight) from 15th to 28th day⁹⁻¹⁰. Group IV & V animals served as curative regimen and received ethanolic extract of the plant of *Solanum virginianum* at a dose of 200 mg/kg and 400 mg/kg body weight from 15th day to 28th day. Group VI & VII animals were served as preventive regimen and received ethanolic extract of the plant of *Solanum virginianum* at a dose of 200 mg/kg and 400 mg/kg body weight from day 1st day to 28th day. Both the extracts were administered once daily by oral route.

ASSESSMENT OF ANTIUROLITHIATIC ACTIVITY

Collection and analysis of urine

Urine samples were collected on 28th day for 24 h by keeping the animals in individual propylene metabolic

cages. Animals had free access to drinking water during the urine collection period. The collected urine was analyzed for calcium and phosphate using standard methods. The volume of urine collected from all groups was recorded. Further, microscopy of the urine was performed to identify the presence of crystals.

Serum analysis

After the experimental period, the blood was collected from the retro orbital puncture of rat eye under ether anesthesia. Serum was separated by centrifugation of the blood samples at 10,000 RPM for 10 minutes and analyzed for creatinine, uric acid and BUN using standard methods.

Effect of *S. virginianum* plant extracts on the kidney weight

The weights of the kidney of normal, induced, standard drug treated and extract treated group rats were weighed. The Group II animals gained the least body weight as compared to the normal control and extract treated groups. In addition, the wet weight of kidneys were taken and compared between the groups.

Histopathology

To confirm the incidence of urolithiasis the animals were sacrificed and their kidneys were isolated and subjected to histopathological studies. The kidneys were cleaned off from extraneous tissue and transferred to 10% neutralized formalin solution (pH 7.4). Sections of kidney was fixed in paraffin, stained with hematoxylin and eosin and observed for histopathological studies¹¹.

Statistical analysis

Statistical analysis was carried out using Graphpad Pism (version 5) software. Results were expressed as mean \pm SEM. Groups of the data were compared applying one-way ANOVA followed by Dunnett's Multiple Comparison test. Differences between the data were considered significant at $P < 0.05$.

RESULTS

Antirolithiatic study

Urinary excretion of calcium and phosphorous

In the present study, chronic induction of EG (0.75% v/v) to male Spargue dawley rats resulted in significant ($P < 0.001$) increase in urinary excretion of

calcium and phosphate. Whereas the cystone-treated group III animals were shown significant reduction in calcium ($P < 0.0001$) and phosphate ($P < 0.001$) levels. Similarly treatment with *Solanum virginianum* significantly lowered the elevated levels of calcium ($P < 0.0001$) and phosphate ($P < 0.0001$) in urine curative regimens and preventive regimen as compared to EG induced group II animals (**Table 1**).

Serum analysis

The blood urea nitrogen (BUN), serum creatinine and serum uric acid levels were significantly ($P < 0.0001$) increased in calculi-induced group II animals. While the BUN, serum creatinine and serum uric acid levels were significantly ($P < 0.001$) decreased in cystone-treated group III animals. However, the BUN and serum creatinine levels were significantly ($P < 0.0001$) decreased in both preventive and curative regimen groups. It is also found that there is no significant reduction in serum uric acid levels in curative regimens (Group IV and Group V), but the preventive regimens shows a significant ($P < 0.0001$) reduction in elevated serum uric acid levels (**Table 1**).

Kidney Weights and Urinary Volume

The kidney weight was significantly ($P < 0.001$) increased in ethylene glycol induced group –II animals when compare to the control group animals. Whereas the standard treated group animals was shown significant ($P < 0.001$) reduction in the kidney weight when compared to the EG induced group II animals. Similarly a significant ($P < 0.0001$) decrease in the kidney weight is also identified in *Solanum virginianum* treated preventive and curative regimens (**Table 2**).

The urinary volume was significantly ($P < 0.001$) decreased in ethylene glycol induced group-II animals when compared to the control group animals. Whereas the standard treated group animals was shown significant ($P < 0.01$) increase in urine output when compared to the EG induced group II animals. Similarly a significantly increase the urinary volume is also identified in *Solanum virginianum* treated preventive regimen ($P < 0.0001$) and curative regimen ($P < 0.05$) animals (**Table 2**).

Histopathological studies

Histopathological studies of kidneys clearly revealed that the tissue section of Group I rats showing normal size tubules with single epithelial lining along the margin. Whereas the Group II rats showed dilated

tubules and degeneration of epithelial lining with presence of crystals. But the kidney specimen from

standard and extract treated groups showed characters similar normal control group (Figure 1).

Table: 1 Effect of *Solanum virginianum* extracts on urinary and serum parameters in control and experimental urolithiasis

Parameters	Normal Group-I	Inducer Group-II	Standard Group III	Curative regimen		Preventive regimen	
				Group-IV (200 mg/k.g)	Group-V (400 mg/kg)	Group-VI (200 mg/kg)	Group-VII (400 mg/kg)
Urine (mg/dl)							
Calicium	9.18±0.18	21.0±20.36	11.77±0.36 ^{***}	16.52 ±0.13 ^{**}	15.12±0.12 ^{**}	14.12±0.13 ^{***}	12.58±0.17 ^{**}
Phosphorous	2.005±0.02	3.938±0.05	2.520±0.02 ^{**}	3.477±0.01 ^{**}	3.323±0.05 ^{**}	2.825±0.01 ^{**}	2.723±0.01 ^{***}
Serum							
Blood urea nitrogen	18.95±0.805	39.47±1.702	22.68±0.419 [*]	33.55±2.325 ^{***}	27.01±1.24 ^{***}	24.01±0.42 ^{***}	2.76±0.365 ^{***}
Serum creatinine	2.283±0.08	4.433±0.16	2.033±0.13 ^{**}	4.033±0.20 ^{ns}	2.333±0.09 ^{***}	2.800±0.23 ^{***}	1.800±0.14 ^{***}
Uric acid	4.175±0.17	5.812±0.19	4.797±0.13 ^{**}	5.613±0.14 ^{ns}	5.823±0.09 ^{ns}	4.700±0.12 ^{**}	3.132±0.18 ^{**}

The values are expressed as Mean ± SEM (n=6).

Comparisons were made between: Control Vs Group-II & Group-II Vs Group-III, IV, V, VI, and VII.

Statistical significant test for comparisons was done by ANOVA, followed by Dunnet'- 't'test

p-values ***p<0.001, **p<0.01 and *p<0.05. Ns – Non significant

Table 2: Effect of *Solanum virginianum* Plant extracts on the Urinary volume and kidney weight

Parameters	Normal Group-I	Inducer Group-II	Standard Group III	Curative regimen		Preventive regimen	
				Group-IV (200 mg/k.g)	Group-V (400 mg/kg)	Group-VI (200 mg/k.g)	Group-VII (400 mg/kg)
Urinary Volume	31.94±1.22	15.08±0.81	25.37±1.05 ^{***}	24.34±1.35 ^{***}	25.67±0.92 ^{***}	21.56±0.95 ^{**}	19.86±1.62 [*]
Kidney Weight	32.73±0.05	46.51±0.10	39.00±0.16 ^{***}	44.08±0.04 ^{***}	43.16±0.01 ^{***}	42.03±0.08 ^{***}	40.62±0.01 ^{***}

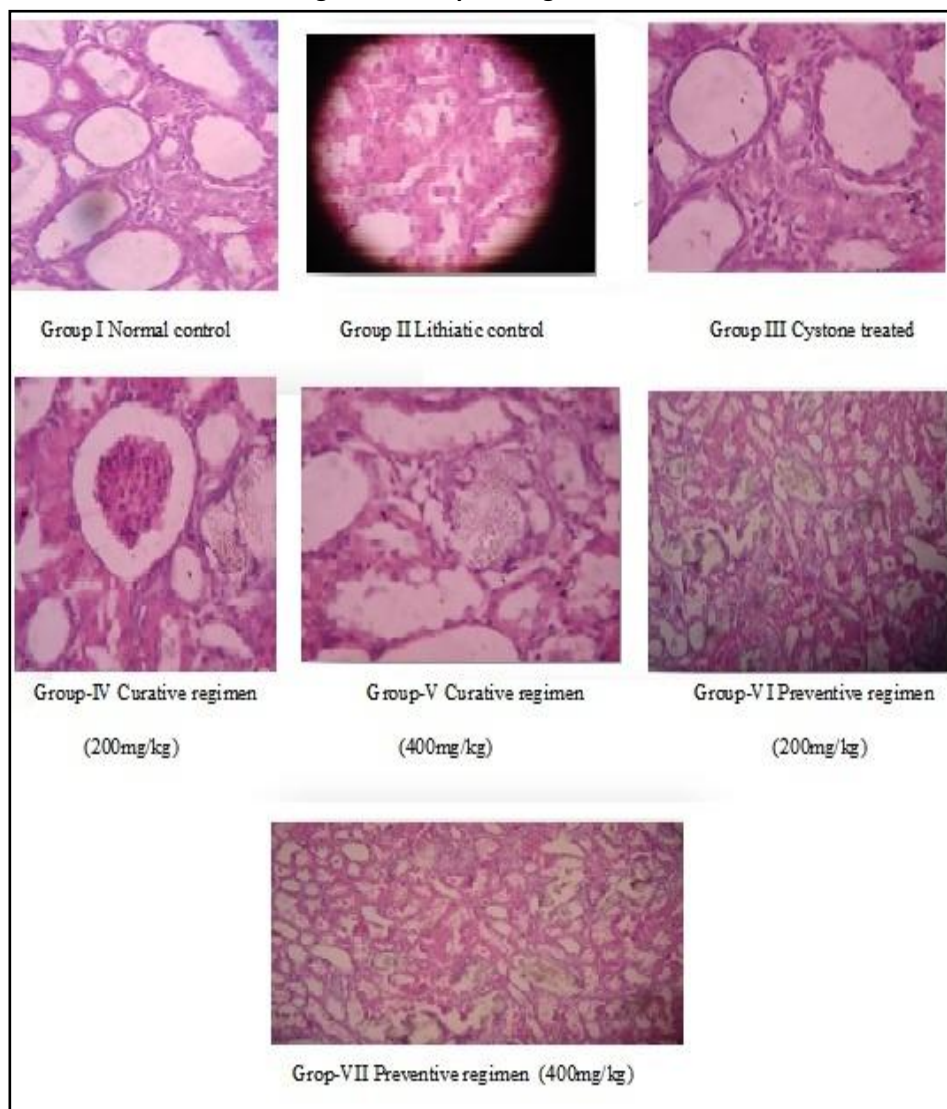
The values are expressed as Mean ± SEM (n=6).

Comparisons were made between: Control vs Group-II & Group-II vs Group-III,IV,V,VI,VII.

Statistical significant test for comparisons was done by ANOVA, followed by Dunnet'- 't'test

p-values ***p<0.001, **p<0.01 and *p<0.05. Ns – Non significant

Figure 1: Histopathological studies



DISCUSSION

Urolithiasis can be produced in rats by induction of acute or chronic hyperoxaluria by using a variety of agents such as ethylene glycol, sodium oxalate, ammonium oxalate, hydroxyl-L-proline and glycolic acid¹². Kidney being the principal target for EG induced toxicity. EG is broken down *in-vivo* into four organic acids viz., glycolaldehyde, glycolic acid, glycooxalic acid and oxalic acid leading to hyperoxaluria which is the main initiative factor for lithiasis¹³. Therefore in the present study, EG was preferred to induce lithiasis. Administration EG to the experimental animals for 28 days resulted in substantial elevation of oxalate and deposition of microcrystal's in kidney. In addition, oxalate

precipitates as a calcium oxalate crystals in kidney since the oxalate metabolism is considered almost identical between rats and humans.

Calcium and phosphate play a vital role in renal calculogenesis. In EG induced rats, the urinary excretion of calcium, phosphate was significantly increased. The increase in calcium and phosphate excretion could be due to defective tubular reabsorption in the kidneys¹⁴. While treatment with standard, curative and preventive regimens of *S. virginianum* markedly reduced the levels of these ions, suggested protective effect of *S. virginianum* against urolithiasis.

In urolithiasis, the calculi formed in the renal tissue leads to obstruction in the urinary system that

decreases the glomerular filtration rate (GFR) and cause an accumulation of certain waste products like nitrogenous substances e.g., BUN, creatinine and uric acid in the blood¹⁵. Marked renal damage was seen in EG induced rats indicated by decreased GFR, significant kidney weight gain and elevated serum level of BUN, creatinine, and uric acid. However treatment with ethanolic extracts of *S. virginianum* plant extracts in both curative and preventive regimens caused diuresis along with loss of kidney weight and also decreased the elevated serum level of BUN, creatinine and urea.

The findings of the histopathological studies suggested that no microcrystalline deposition and deposition and kidney damage in the *S. virginianum* extract treated groups all these observations enabled us to confirm the preventive curative potential of *S. virginianum* on ethylene glycol induced lithiasis. In conclusion, the ethanolic extract of *S. virginianum* has both preventive as well as curative property in urolithiasis of rats. These finding, thus prompt the necessity for further study to carry out the antilithiatic effect of *S. virginianum* by isolation of constituents and find out the actual constituent that active against stone formation.

REFERENCES

- Mohammed Touhami, Amine Laroubi, Khadija Elhabazi, Farouk Loubna, Ibtissam Zrara, younes Eljahiri et al. Lemon juice has protective activity in a rat urolithiasis model. *BMC Urol* 2007; 7: 18.
- Christina AJM, Ashok K, Packialakshmi M, Tobin GC, Preethi J Muruges N. Antilithiatic effect of *Asparagus racemosus* willd on Ethylene Glycol-Indued Lithiasis in Male Albino Wistar Rats. *Methods find Experimental clinical pharmacology* 2005; 27 suppl 9: 633-638
- Aroujo Viel T, Domingos CD, Da Silvamonteiro AP, Riggo Lima-Landman MT, Lapa AJ, Souccar C. Evaluation of the antiurolithiatic activity of the extract of *Costus spiralis* Roscoe in rats. *Journal of Ethnopharmacology* 1999; 66 suppl 2: 193-198.
- Kishimoto T, Yamamoto K, Sugimoto T, Yoshihara H, Maekawa M. Side effects of extracorporeal shock-wave exposure in patients treated by extracorporeal shock-wave lithotripsy for upper urinary tract stone. *European Urology* 1986; 12:308-313.
- Vaidya Ratnam P S Varier's. *Indian Medicinal Plants*. Orient Longman. Vol-5: 164-166.
- Crossland, J. Lewis pharmacology, Churchill Livingstone, New york.: 1980 : pp 137.
- OECD, 2002. Acute oral toxicity. Acute oral toxic class method guideline 423 adopted 23.03.1996. In: Eleventh Addendum to the, OECD, guidelines for the testing of chemicals organization for economical co-operation and development, Paris, June, 2000.
- Sathish R, Natarajan K, Mukesh MN. Effect of *Hygrophila spinosa* T. Anders on ethylene glycol induced Urolithiasis in rats. *Asian J of Pharmaceutical and clinical research* 2010: 3: 61-63.
- Mitra SK, Gopumadhan G, Venkataranganna MV and Sundaram R. Effect of cystone, a herbal formulation on glycolic acid induced urolithiasis. *Phytotherapy research* 1998: 12: 372-374.
- Ravindra VK, Navneet BG, Alagawadi KR, Rudraprabu VS. Ethylene glycol induced urolithiasis in effect of *Moringa oleifera* Lam. Root-wood on rats. *J of Ethnopharmacology* 2006: 105(1): 306-311.
- Onyenmechi JA, Orish EO, Chudi ED, Ejeatuluchukwu OBI, Tobias E, Lasbery A, Ukoha. Effect of Rinbacin extract on rat Kidney. *Biol Pharm. Bull* 2002: 25(8): 1022-1025.
- Khan SR, Animal models of kidney stone formation: an analysis, *World J Urol*, 1997: 15: 236-243.
- Schladt L, Ivens I, Karbe E, Ruhl-Fehlert C, Bomhard E, Sub acute oral toxicity of tetra ethylene glycol and ethylene glycol administered to Wistar rats, *Exp Toxicol Pathol*, 1998:50: 257-265.
- Varalakshmi P, Shamila Y, Latha E, Effect of *Crataeva nurvala* in experimental urolithiasis, *J Elhnopharmacol*, 1990:28: 313-321.
- Khatib N, Dhaval G, Hashilkar N, Rajesh KJ. Antiurolithiatic potential of the fruit extracts of *Carica papaya* on ethylene glycol induced urolithiatic rats. *J Pharmacy Research* 2010: 3(11): 2772-2775.



***Corresponding Author:**

Dr. Krishna Mohan Chinnala

Professor & Principal
St. John College of Pharmacy,
Yellapur, Hasanparthy, Warangal-506371,
Andhra Pradesh, INDIA.