International Journal of Pharmacy and Biological Sciences-IJPBS™ (2019) 9 (2): 1131-1136
Online ISSN: 2230-7605, Print ISSN: 2321-3272
Research Article | Biological Sciences | Open Access | MCI Approved
UGC Approved Journal

Estradiol Valerate Dose Determination for PCOS Induction

Mukilan Ramadoss, Manibalan Vijayaraman and Angelie Jessica Subbiah

Assistant Professor, Department of Physiology, CSI College of Dental Sciences and Research, Madurai, India.

Assistant professor, Department of Physiology, Vinayaka Missions Medical College and Hospital, Karaikal, Pudhucherry, India.

Assistant Professor, Department of Anatomy, CSI College of Dental Sciences and Research, Madurai, India.

Received: 10 Jan 2019 / Accepted: 9 Mar 2019 / Published online: 1 Apr 2019
Corresponding Author Email: mukilan17@gmail.com

Abstract

Animal model polycystic ovary are used to study the etiological and pathophysiological, perform drug testing and investigative effect of treatment in various ways that are not possible in humans as well as to carry out pre-clinical studies. In order to resemble the pathophysiology of the syndrome several models in various mammalian and primate species have been developed during the decades, each having its own advantages and disadvantages. Estradiol valerate (EV) is utilized to create PCOS by prompting hormone variations from the normal. EV, which is presented as a prodrug, is an ester derived from 17β- estradiol. A single intramuscular infusion of estradiol valerate (EV) in cycling rats brings about loss of oestrus cyclicity, anovulation, and the development of follicular cysts. These progressions showed by the steroid-incited polycystic ovary (PCO) share considerably a lot of the endocrinological and morphological variations as found in human PCOS.

Keywords

Estradiol Valerate, Polycystic ovary syndrome.

*****

INTRODUCTION

In a noncarcinogenic human ovary, increased secretion of androgen causes PCOD. Such a hyper secretion may result from a nonpulsatile, steady elevated level of circulating LH or a disturbance in the activity of neurotransmitters in the hypothalamus. In studying the pathophysiology of PCOD in people, one must know about the restrictions for controlling the hypothalamic-pituitary axis. In spite of the fact that the rodent is a polytocous rat, the female has a consistent ovarian cyclicity of 4 or 5 days, with distinct proestrus, estrus, metestrus and diestrus stages. Because of the fact that PCOD can be experimentally produced in the rodent, that species is a opt model for studying the pathophysiology of human PCOD (Mahajan, 1988).

In the event that the abundance androgen secretion is reduced by one of the methods, and ovulatory cycles are generally reestablished. An extensive variety of experimental manipulations brings about an anovulatory polycystic ovarian (PCO) condition in the rodent (rat). In spite of the fact that PCO has been examined in some of these models, research has fixed on the condition after it is well established (Brawer et al., 1986).

These PCOD models and their legitimacy have been portrayed: Administration of estradiol-valerate, DHA, exposure to consistent light (LL), and are neonatally androgenized. The generation of the polycystic ovarian condition in the rats by the infusion of estrogens or androgens in animals, or estradiol or DHA in adult rats, cause an appearance of the persistent estrus state by distressing the metabolic and physiologic processes (Mesbah et al., 2011). In spite of the fact that the anatomical and physiology changes of the ovary appear like those of PCOD patients, the dynamic degeneration of the hypothalamus and the altered reaction of the pituitary to luteinizing hormone releasing hormone (LHRH) make this model inappropriate to study the hypothalamic-pituitary-ovarian axis in the polycystic ovary condition.

Exposure to a single dose, of estradiol valerate (EV) in rat can cause irregularality in reproductive cycles with the lack of ovulation and polycystic ovaries presenting with high number of atretic follicles and cysts. These ovarian changes are similar to those of PCOS in women (Walters et al., 2012). Though various studies had demonstrated the dose of EV for PCOS induction in various strains of rats and mouse models. 4mg/kg bw of EV injection can develop PCOS with the appearance of anovulation, and cystic appearance in ovary and also shown alterations in the sex steroids and anderogen levels (Leila Amini et al., 2012). 2mg/kg bw of EV injection has also shown the appearance of cystic ovary and uterine changes (Ghadire and Zahra, 2017). With the difference in dose and dissimilarity among the earlier work. A preliminary study was done to determine the working concentration of EV in wistar albino rats which were raised in the local environment.

MATERIALS AND METHOD:

After getting approval from animal ethical committee. Fourty 8 weeks old adult virgin Wistar albino rats (150 -200 gms body weight, were obtained from the animal house of the KM college of Pharmacy, Madurai. Were kept in a central temperature-controlled animal care room with (22±2°C) with relative humidity of (45% to 55%), under 12 hours of on and 12 hours off light cycle. In a group, 4 rats are housed in each cage with easy access to food and water.

Chemical Used: Estradiol Valerate (EV) (Progynon Deport – German remedies, India)

Study Design: The experimental animals (n = 40), were divided into 4 groups (n = 10) received a different dosage of EV as follows.

Group	EV dosage for injection
Group A	2 mg of EV/ kg bw
Group B	3 mg of EV/ kg bw
Group C	4 mg of EV/ kg bw
Group D	4.5 mg of EV/ kg bw

Table 1: EV Dosage groups.

Injection of EV: A different concentration of EV was injected intramuscularly on day 1.

Vaginal Smear Cytology:

After injection the vaginal smear cytology was performed in all the animals in the morning between 9 am to 11 am using a cotton swab technique (Cora et al., 2015). The vaginal swabs were taken and spread over slides and examined under microscope to determine the estrus cycle stage of the rats. The proportion of different cell types of vagina indicates the stage of the cycle.

Estrus: The cells were large and often non nucleated, **Metestrus:** Large number of leukocytes, small number of large nongranular and non-nucleated epithelial cells, **Diestrus:** Small number of epithelial and cornified cells, **Pro estrus**: Round nucleated epithelial cells.

The acyclicity of the rats estrus cycle was confirmed by continuous appearance of diestrus stage in vaginal smear cytology.

RESULT

Evaluation of the Ovarian Morphology and Follicle Count

Table 2: Ovary Histology Examination.

Parameters	Group A 2mg/Kg EV mean±SD	Group B 3mg/Kg EV mean±SD	Group C 4mg/Kg EV mean±SD	Group D 4.5mg/Kg EV mean±SD
Number of primary follicles	6.34±2.87	5.56±2.68	3.95±2.36*	3.75±1.06*
Number of preantral follicles	1.06±1.37	1.04±0.16	1.01±0.45*	1.06±0.95*
Number of antral follicles	4.16±3.42	3.36±1.36	3.65±3.87	3.24±2.69
Number of preovulatory follicles	0.24±0.43	0.16±0.32	0.05±0.12	0.00±0.00
Number of Corpus luteum	6.38±6.34	5.06±3.72*	4.01±3.36*	2.48±2.67*
Number of Ateritic follicles	4.96±3.54	6.78±5.36*	14.82±6.73**	18.01±7.83**
Number of Healthy follicles	11.56±3.84	10.43±6.85	5.63±1.86**	4.52±3.83*

Abbreviations: CL, Corpus Lutea; AF, Atretic follicles; HF, Healthy follicles

Table 2: Comparision of different dosage group of EV for PCO induction, group D showed a significant increase (p<0.05) in number of atretic follicle and significant* reduction in number of primary antral follicles, preovulatory follicles, corpus luteum and healthy follicle when compare to other groups (A,B & C). However, there are no significant changes was observed in pre antral and antral follicles in all the groups.**

Sixty days after the induction with EV, the rats in four groups were anesthetized with ether and their ovaries were expelled and isolated from adherent surrounding tissues. The ovaries were fixed for a day in 10% formaldehyde. After tissue handling as indicated by standard protocols, ovaries were embedded in paraffin and were longitudinally cut into 5 µm thickness. For tissue staining, we utilized hematoxylin and eosin. These ovarian sections were seen under a light microscope (Olympus, Japan) (×100 and ×40 magnification).

Follicles were characterized as primarily if they had a solitary layer of cuboidal and granulosa cells; preantral if they had a couple of little spaces loaded with follicular liquid, antral if they had a single layer with vast antral space; preovulatory if oocyte was presented with a rim of cumulus cells (Myers et al., 2004); atretic, if follicles were disfigured or oocyte was missing or pyknotic nuclei exhibited in granulosa cell; and corpus lutea.

A wide range of follicles were checked in every ovary. At that point all follicles were named as healthy (primary, antral, preantral and preovulatory) or atretic (Radavalli et al., 2011).

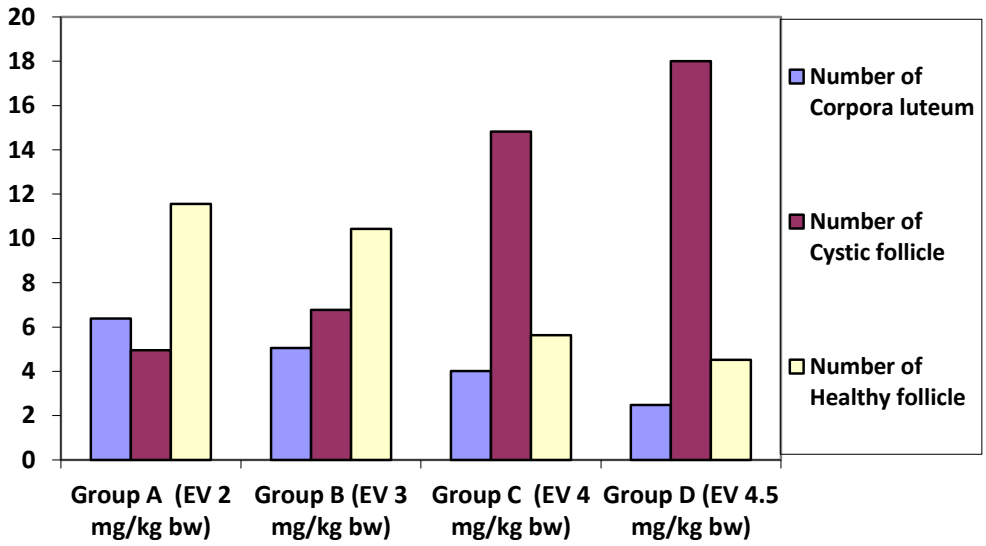

Figure 1: Comparison among the different dosage group of estradiol valarate, there was a significant (P<0.05) reduction in number of corpus lutea and healthy follicle in group D when compared to other groups (A –C), significant increase in number of cystic follicles in group D, comparing to other groups.

Histopathology Of Ovary – [Group - D (4.5 Mg Of EV)] PCO Formation

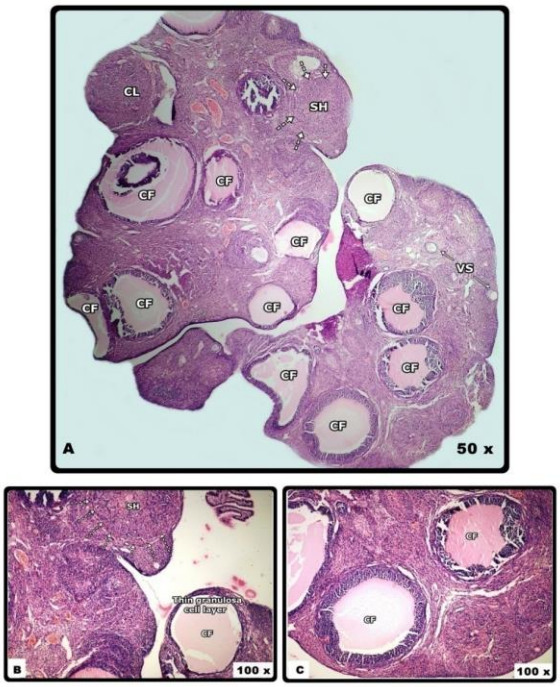

Figure 2: Photomicroscope image of transverse histological sections of ovary in dosage of 4.5mg of EV. (A 50X B & C 100 x) Many cystic follicles, with thin layer of granulose cell layer and cell debris present inside the cysts. Stromal hyperplasia, vacuolated stroma, atretic follicle and few corpus luteum.
Abbreviations: CF – Cystic follicle, VS – Vaculated stroma, SH – Stromal hyperplasia and CL – Corpus luteum.

DISCUSSION:
In the present study histopathological examination of ovary revealed that optimal dose of EV 4.5mg that can induce PCOS like morphological changes in the ovary; this dose was doubled than the dose used by (Brawer et al., 1986) to obtain fully formed PCO in rats. The reason for dose difference might be due to the strain of rat or may be due to different lab environment and the estradiol valerate preparations that may vary.

In this preliminary study, the morphological examination of ovaries demonstrated that the exposure of young adult female rats to a single dosage of EV can prevent ovulation. In spite of the absence of critical contrasts between the groups with respect to preantral and antral follicles, in-accordance with other studies (Mukilan et al., 2016, 2017) the preovulatory follicle and corpus lutea were significantly lower in 4 and 4.5 mg/kg EV-treated rats. This can be identified with the reduced ovulatory rate, clarifying the poor fertility rate in these groups. Earlier 4.5mg/kg

It appears these outcomes might be because of increased level of serum oestradiol concentration, which can give an inappropriate hormonal condition to for developing follicles (Stener et al., 2005). Impaired follicle development seems to emerge from the increased luteinizing hormone (LH), or from low FSH secretion and high androgen level (Johansson & Stener-Victorin, 2006). In addition, estrogen can alter ovulatory cycles by hypothalamic disturbances (Kasturi et al., 2009).

Polycystic ovary is a disorder in normal follicle development. In PCOS, follicles are arrested in immature stages and consequently dominant follicle determination will not occur. This might be because of absence of +ve estrogen feedback to the hypothalamus and to pituitary axis. As a result, LH surge will not occur and therefore the ovulation will be disrupted (Oakley et al., 2011). The changes after single EV induction can be due to the action of peripheral sympathetic neurons that innervates the ovaries. Accordingly of increased sympathetic activity, PCOS will develop (Zangeneh et al., 2012; Lara et al., 1993).

5.6: CONCLUSION

The present study showed that PCOS model can be produced in adult rats by a single dose injection of 4.5mg/kg bw of EV. This easy handling EV induced PCO rat model may enable us for various PCOS studies.

REFERENCES:

1. Mahajan DK, Polycystic ovarian disease: animal models., Endocrinol Metab Clin North Am. 1988; 17:705-32.
2. Brawer JR, Munoz M, Farookhi R., Development of the polycystic ovarian condition (PCO) in the estradiol valerate-treated rat., Biol Reprod 1986; 35:647-55.
3. F Mesbah , M Moslem, Z Vojdani, H Mirkhani., Estradiol Valerate-induced Polycystic Ovary Syndrome: An Animal Model Study. Armaghane Danesh 2011; 15:325-334.
4. Walters KA, Allan CM, Handelsman DJ. Rodent models for human polycystic ovary syndrome. Biol Reprod 2012; 86:149-156.
5. Leila Amini, Najmeh Tehranian , Mansoureh Movahedin, Fahimeh Ramezani Tehrani , Haleh Soltanghoraee., Polycystic Ovary Morphology (PCOM) in Estradiol Valerate Treated Mouse Model. Int journal of women health 2016; 4:13–17.
6. Ghadire Mirabolghasemi, and Zahra Kamyab., Changes of The Uterine Tissue in Rats with Polycystic Ovary Syndrome Induced by Estradiol Valerate. Int J Fertil Steril 2017; 11:47–55.
7. Cora MC, Kooistra L, Travlos G., Vaginal Cytology of the Laboratory Rat and Mouse: Review and Criteria for the Staging of the Estrous Cycle Using Stained Vaginal Smears. Toxicol Pathol 2015; 4:776-93.
8. Myers M, Britt KL, Wreford NGM, Ebling FJP, Kerr JB. Methods for quantifying follicular numbers within the mouse ovary. Reproduction 2004; 127:569- 580.
9. Radavelli-Bagatini S, Blair AR, Proietto J, Spritzer PM, Andrikopoulos S. The New Zealand obese mouse model of obesity insulin resistance and poor breeding performance: evaluation of ovarian structure and function. J Endocrinol 2011; 209:307-315
10. Brawer JR, Naftolin F, Martin J, Sonnenschein C. Effects of a single injection of estradiol valerate on the hypothalamic arcuate nucleus and on reproductive function in the female rat. Endocrinology 1978; 103:501-512.
11. Brawer JR, Munoz M, Farookhi R. Development of the polycystic ovarian condition (PCO) in the estradiol valeratetreated rat. Biol Reprod 1986; 35:647-655.
12. Mukilan R, Gunasekaran R, Angelie Jessica S, C Natrajan. Heart Rate Changes in Electroacupuncture Treated Polycystic Ovary in Rats. Journal of clinical and diagnostic research: 10 (3), CF01
13. Mukilan R, Gunasekaran R. Effect of Electroacupuncture on Anovulation, Epinephrine and Norepinephrine Levels in Drug Induced Polycystic Ovary Rats. International Journal of Science and Research. 6 (1), 2209- 2212
14. Stener-Victorin E, Ploj K, Larsson BM, Holmäng A. Rats with steroid-induced polycystic ovaries develops hypertension and increased sympathetic nervous system activity. Reproductive Biol Endocrinol 2005; 3:44-49.
15. Johansson J, Stener-Victorin E. Polycystic ovary syndrome: Effect and mechanisms of acupuncture for ovulation induction. Evidence-Based Complementary and Alternative Medicine 2013; 762615:14.
16. Azziz R, Nestler JE, Dewailly D. Androgen excess disorders in women: Polycystic ovary syndrome and other disorders. 2nd ed. Totowa, New Jersey: Humana Press; 2006.
17. B. S. Kasturi, S. M. J. MohanKumar, M. P. Sirivelu, P. S. MohanKumar., Chronic Exposure to Low Levels of Oestradiol-17β Affects Oestrous Cyclicity, Hypothalamic Norepinephrine and Serum Luteinising

Hormone in Young Intact Rats., Journal of nuero endo 2009; 21:568-577.
18. Oakley O, Lin P, Bridges P, Ko C. Animal models for the study of polycystic ovarian syndrome. Endocrinol Metab 2011; 26:193-202.
19. Zangeneh FZ, Naghizadeh MM, Minaee B, Aminee F. PCOS & symptomatic outcome: role of the central and peripheral nervous system in ovarian function of rat. Asian J Pharm Clin Res 2012; 5:26-32.
20. Lara HE, Ferruz JL, Luza S, Bustamante DA, Borges Y, Ojeda SR. Activation of ovarian sympathetic nerves in polycystic ovary syndrome. Endocrinology. 1993; 133:2690-2695.