

ANEURYSMAL BONE CYST OF THE LATERAL END OF CLAVICLE IN A FOURTEEN YEAR OLD BOY – CASE REPORT

Nagakumar J S¹, Nazeer BS², Samarth Arya³

¹Assistant Professor, Department of Orthopaedics, SDUMC, Kolar, India

²Professor, Department of Orthopaedics, SDUMC, Kolar, India

³Jr. Resident, Department of Orthopaedics, SDUMC, Kolar, India

ABSTRACT

Aneurysmal bone cysts are enigmatic lesions of unknown cause and presentation and are difficult to distinguish from other lesions. We present a case of aneurysmal bone cyst involving clavicle. It presented difficulties in diagnosis because of the uncommon location. The boy was treated surgically with curettage and autologous bone grafting as discussed.

KEY WORDS

Aneurysmal bone cyst (ABC), Clavicle.

INTRODUCTION

Primary bone tumours of flat bones like clavicle are rare. True benign tumours are much uncommon than metastatic or malignant lesions. Aneurysmal bone cyst (ABC) is a benign but locally aggressive lesion of the bone which accounts for 3% of all bone tumours. Its histology is characterized by multiloculated cystic tissue filled with blood. Etiology and pathogenesis of this lesion remains unclear and it affects 0.14 per lakh every year¹. It is a disease mainly of the young with a peak incidence in the second decade. However it may on occasion occur in the elderly and the very young². ABC may involve almost any bone but the most frequent sites are long tubular bones and vertebrae. Among flat bones, the pelvis and scapula are well known locations. Despite very characteristic radiological features, the unusual age coupled with the uncommon site led to diagnostic difficulties in present case. The clavicle is a rare site for these lesion and not many have been reported in literature. Smith in 1965

could find only 25 cases in the medical literature, textbooks and atlases³. Because of these factors, this report is felt to be of interest.

CASE REPORT

A 14 year old boy presented with swelling in his left clavicular region that had been increasing in size progressively since last six months to reach the size of a lemon. The swelling at the acromial end had distinct edges, was smooth surfaced (**Fig. 1**) and overlying skin temperature was normal. The mass was bony hard, non-tender and the skin over the swelling was pinchable. Swelling was immobile and Egg shell crackling sensation was noted. No functional impairment, skin changes or dilated veins or signs of neurological deficits and lymphadenopathy was noted. There was no history of trauma or history of recurrent fever and loss of weight. No other lumps or swellings were present anywhere else.

Radiograph showed a cystic expansile lesion of the lateral end of the left clavicle bounded by a

thin layer of bone (**Fig. 2**). Based on the appearance various possibilities including simple bone cyst, ABC, eosinophilic granuloma, and enchondroma were considered.

Basic hematological work up including complete blood count, ESR, CRP and alkaline phosphatase were within normal limits. The lesion was further studied with MRI left shoulder (**Fig.3**) and fine needle aspiration cytology. MRI pointed to the possibilities of ABC, Giant cell tumour and Chondroblastoma. FNAC report came out to be inconclusive.

Therapeutic options which were considered at that point were resection of lesion and curettage with autologous bone grafting. The conservative approach was preferred as resection could have resulted in weakening of the shoulder. Intraoperatively, initially a 10cc disposable

syringe was used to aspirate the contents of the cavity. The content was found to be a blood-fluid (**Fig. 4**).

The lesion was approached after incising the periosteum longitudinally. It was a multiloculated cyst containing streaks of thrombi (**Fig. 5**). The inner wall was curetted and electrocautery done to seal the bleeding walls of the cavity. Cavity was further irrigated with iodine containing alcohol solution and cavity was filled with cortico-cancellous strip of autologous iliac crest bone graft. Periosteal tube was repaired and limb was immobilized in cuff and collar sling. Postoperative period was uneventful. The preoperative diagnosis was confirmed with the histopathological examination of the curetted specimen.

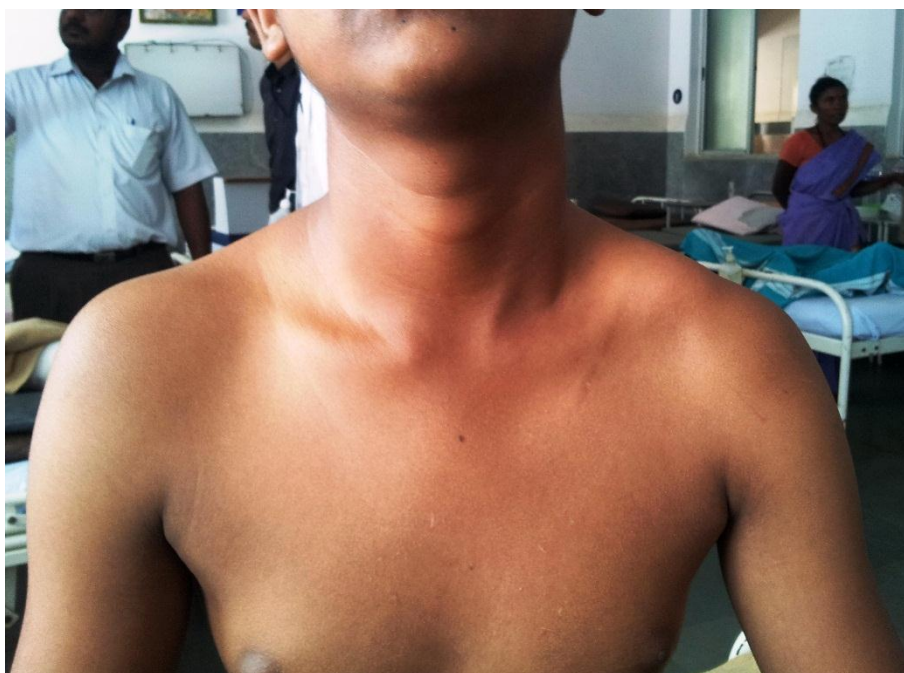

Figure 1: Photograph depicting swelling at the left clavicular region.

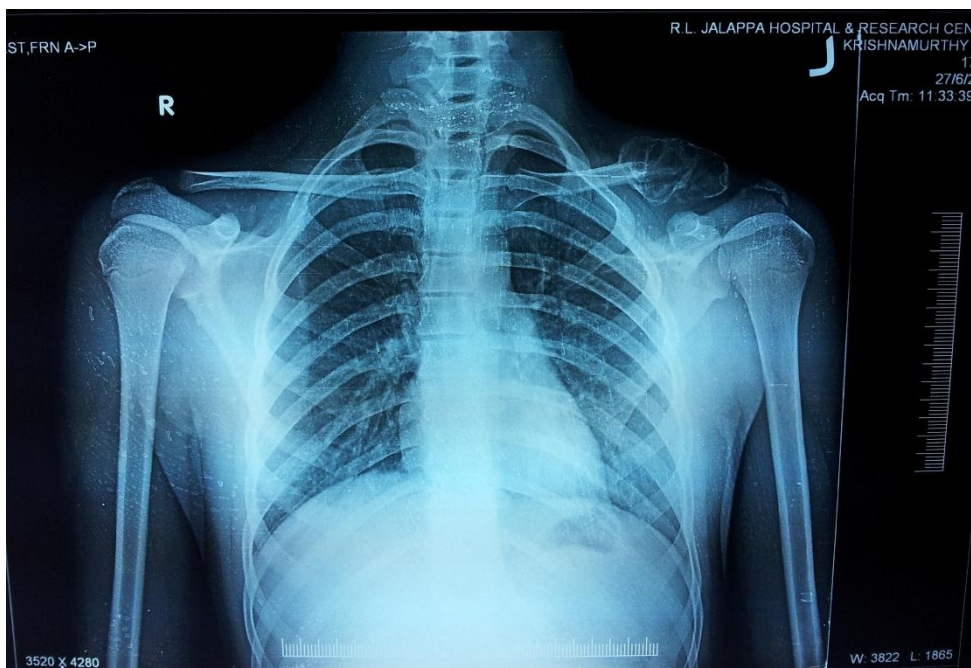


Figure 2: Radiograph showing cystic expansile lesion bounded by a thin layer of bone at the lateral end of the left clavicle.

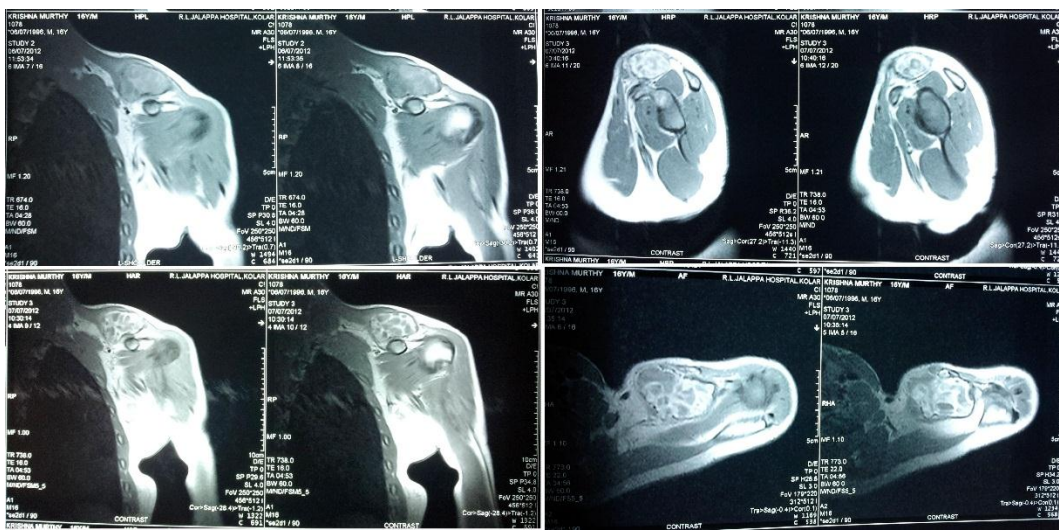


Figure 3: MRI Left shoulder (Plain and contrast) Scan showing multilobulated T1 hypointense, T2 hyperintense arising from end of left clavicle with destruction of lateral end and peripheral enhancement, central non-enhancing areas.

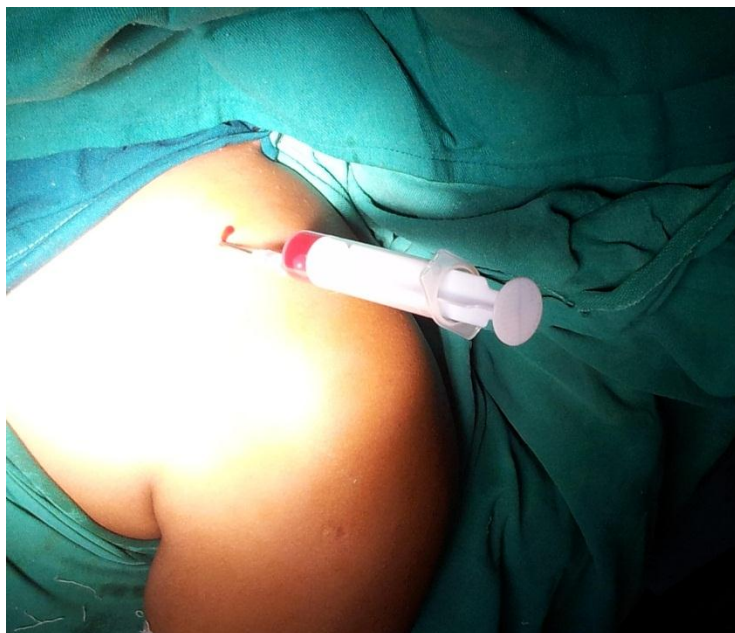

Figure 4: Intraoperative photograph showing blood-fluid in the cyst.

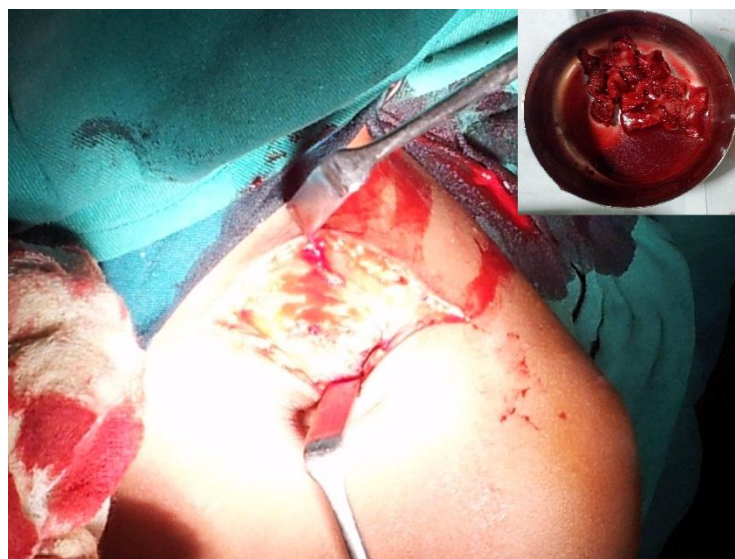

Figure 5: Photograph depicting multiloculated cyst containing streaks of thrombi.

DISCUSSION

Despite the long experience of orthopedicians, radiologists and pathologists, there is limited knowledge regarding the cause of the lesion, its natural history, and the results of treatment⁴⁻⁸. An interesting theory about the aetiology of primary

ABCs is that the lesions occur because of haemorrhage in the bone as a result of increased venous pressure. The haemorrhage is thought to lead to osteolysis. The osteolysis, in turn, causes further haemorrhage, leading to exponential growth of the tumour. This theory would perhaps

explain why ABCs are uncommon in the clavicle and bones of the facial skeleton, where the venous pressure is low. On the other hand, ABCs are common in long bones, where the venous pressure is high and the marrow content is greater⁹. Conventional thinking; however, ascribes these lesions either to a reaction to physical injury, which may sometimes be remote, or to a vascular disturbance. The concept that the lesion represents a vascular degenerative process for some benign bone lesions is an attractive one, but the pathologic findings, with rare exception, do not really support this proposal. Few pathologic specimens contain tissues that are highly characteristic or diagnostic of giant cell tumor, chondroblastoma, hemangioma, osteoblastoma, non ossifying fibroma, chondromyxoid fibroma & others^{6, 7, 8, 10}. Thus, it is often thought that ABC is more of a pathophysiological change in a pre-existing primary bone lesion rather than a single, unique entity¹¹.

Difficulty can occur in diagnosing these lesions. The imaging studies, even CTs and MRIs, sometimes do not provide clearly diagnostic criteria for the diagnosis of ABC, and ABC is sometimes added on to a list of diagnoses including eosinophilic granuloma, giant cell tumor, non ossifying fibroma, unicameral bone cyst, fibrous dysplasia, chondroblastoma, chondrosarcoma, chondromyxoid fibroma, Ewing's tumour etc.^{6, 7, 12}.

In the past, curettage alone was employed in the treatment later methods like saucerisation, resection, radiotherapy, cryotherapy and vascular occlusion are being employed. Nevertheless, there is no consensus among treating physicians regarding how these methods should be used. As a result, there are quiet contradictory reports regarding results and complications¹³. Resection of lesion offers low recurrence rate but this option cannot be exercised everywhere. A

combination of cryosurgery and curettage has been reported by few authors that reported local control after the first treatment in 82% patients¹⁴. Radiotherapy can result in radiation induced sarcomas and can cause radiation induced injury to physis¹³. Thus radiotherapy is reserved in cases that cannot be operated because of their location and to prevent damage to the function of important structure⁷. In some cases embolisation of a feeding vessel may help to decrease vascularity, making the surgical procedure less bloody, especially in difficult locations such as spine and pelvis but it is a highly demanding technique and may not be available at all centres. Recurrence rate in young children with ABC may be as high as 100%¹. Autograft implantations or utilization of intercalary allografts are quite successful and for the most part, are used for patients with lesions that are large or seem to threaten the integrity of the bone. Our patient responded nicely to this form of treatment and we feel that this case enriches existing data regarding treatment option of an ABC in an unusually young patient and in unusual location.

REFERENCES

1. Leithner A, Windhager R, Lang S., Aneurysmal bone cyst: A population-based epidemiologic study and literature review. *Clin Orthop Relat Res.* 1999; 363:176-79.
2. Dominok G. W., Knoch H. G., Manza B., Schulze K. J., Die aneurysmatische Knochencyste. *Langenbecks Archiv für Chirurgie.* 1971; 328: 153-168.
3. Smith J, Aneurysmal bone cyst of clavicle. *Br J Radiol.* 1977; 50:706-9.
4. Aho HJ, Aho AJ, Einola S: Aneurysmal bone cyst: A study of ultrastructure and malignant transformation. *Virchows Arch A Pathol Anat Histol.* 1982; 395:169-79.
5. Aho HJ, Aho AJ, Peliniemi LJ, Ekfors TO, Foidart JM: Endothelium in aneurysmal bone cyst. *Histopathology.* 1985; 9:381-87.
6. Campanacci M: Aneurysmal bone cyst: In Campanacci M - Bone and Soft Tissue Tumors 2nd edn. New York, NY, Springer Verlag, 1999, 812-840.
7. Dorfman HD, Czerniak B: Cystic lesions, In Dorfman HD, Czerniak B: Bone Tumors. St Louis, MO, Mosby, 1998, 855-912.

8. Szendroi M, Aratgto G, Ezzati A, Huttli K, Szavcsur P., Aneurysmal bone cyst: Its pathogenesis based on angiographic, immunohisto chemical and electron microscopic studies. *PatholOncol Res.* 1998; 4:277-81.
9. Boyd RC. Aneurysmal bone cysts of the jaws. *Br J Oral Surg.* 1979; 16: 248-53.
10. Bollini G, Jouve JL, Cottalorda J, Petit P, Panuel M et al., Aneurysmal bone cyst in children: Analysis of twenty-seven patients. *J PediatrOrthop B.*1998; 7:274-285.
11. Kransdorf MJ, Sweet DE. Aneurysmal bone cyst: concept, controversy, clinical presentation, and imaging. *Am J Roentgenol.* 1995; 164: 573-80.
12. Mahnken AH, Nolte Ernsting CC, Wildberger JE, et al: Aneurysmal bone cyst: Value of MR imaging and conventional radiography. *EurRadiol.* 2003; 13: 118-24.
13. Tillman B., Dahlin DC, Lipscomb PR, Stewart JR., Aneurysmal bone cyst: an analysis of ninety-five cases. *Mayo Clin Proc.* 1968; 42:478-95.
14. Marcove R, Sheth DS, Takemoto S, Healey H., The treatment of aneurysmal bone cyst. *ClinOrthop.* 1995; 311: 157-63.



***Corresponding Author:**

Dr. Nagakumar J S

Assistant Professor, Dept of Orthopaedics,
SDUMC, Kolar, India, Ph: 9448543804