

EFFECT OF *IONIDIUM SUFFRUTICOSUM* ON TESTES OF YOUNG ALBINO RAT

^{1*}Senthil Kumar B, ²Vijaya kumar J

¹Department of Anatomy, Vinayaka Mission's Kirupananda Variyar Medical College and Hospital, Salem – 636308

²Department of Anatomy, Saveetha Medical College and Hospital, Chennai.

*Corresponding Author Email: skdrchinu88@gmail.com, chinus.kumar9@gmail.com

ABSTRACT

Fertility is an important factor for male and female in life. Many natural non-toxic herbs were found to enhance the fertility in both the sexes. Some of herbs were studied for its aphrodisiac action. This study involves the effect of the herb *Ionidium suffruticosum* in improving the fertility on male albino rats. In this study *Ionidium suffruticosum* powder were administered orally to the experimental albino rats of Wister lineage (n=10) and compared to the control albino rats (n=10) using various parameters such as weight of animals, dimension of testes, hormonal analysis, semen analysis, histological analysis of testes, diameter of seminiferous tubules and the drug's efficacy was investigated. The administration of the drug showed significant improvement of all the parameters in experimental rats when compared to control rats. The data's were analyzed using student's t test and found to be statistically significant. The herb was found to be effective on the gonads of male albino rats and also it's a safe drug without adverse effect for enhancing the male sexual activity.

KEYWORDS

Infertility, *Ionidium suffruticosum*, Seminiferous tubules, Sperm, Testes, Wister albino rats.

INTRODUCTION

Infertility is a worldwide medical and social problem. It affects above 10-15% of married couples. WHO estimates that there are 60-80 million infertile couples worldwide ¹. Infertility involves not only physical health but more of mental health. Infertility of both the sexes ends up with marital disharmony, divorce or Ostracism ^{2, 3}. In search of suitable solution for the above problem; allopathic medicines proved to be the best remedies but ended up with grave side effects involving various vital organs of the body⁴. Now the whole universe turns back to natural products and greenery things, this made us to go in search of drugs which are mainly of herbal origin. The search ended up with many aphrodisiac herbs which improve fertility and sexual activity, among those *Ionidium suffruticosum* commonly called as Ratna purush was given traditionally for

treating infertility of male in Indian system of medicine. But the effect of this herb was not proved scientifically and documented, so we made an attempt to study the effect of this herb on animals and later carried over to humans if proved to be safe. *Ionidium suffruticosum* has the following phytochemicals such as dipeptide alkaloid, aurantiamide acetate, triterpene, Iso-arborinol, and beta-sitosterol ⁵.

MATERIALS & METHODS

Animal selection and drug administration

The study involves a total of twenty male albino rats (*Rattus norvegicus*) of Wister lineage with an average weight of 130 – 140 gm were housed in the experimental animal unit. The institutional Animal ethical committee approval was taken priority before starting the study. The rats were fed with standard rat feeds and given

fresh water, acclimatized on a 12 hour light & 12 hour dark schedule ⁶. Rats were kept in cages which were cleaned twice a week. The rats were divided into 2 groups control (n = 10) and experimental (n = 10). The cages are labeled with group, weight of the animal and dosage of the drug. About one week was given for the stabilization of rats; drug was administered orally using oral gavage tube. The *lonidium surruticosum* herbs were procured and dried in shades, powdered using pulverizer. The powder was diluted with 1.5ml of sterile water for 25mg and administered orally to the experimental group using oral gavage tube and simultaneously the same amount of sterile water were given orally to control rats (placebo). The drug was administered for 30 days regularly in the morning at a fixed time to all the experimental animals. After the course of drug a rest period of about 10 days were given to all the animals.

Sample collection

The rats were anaesthetized using Xylazine & ketamine⁷. The jugular vein was traced out and using disposable syringe about 2ml of blood was taken. The rat was cut open by midline thoraco-abdominal incision and the heart was perfused with normal saline. After perfusion a midline incision was made on scrotum and the testicles were removed. A fine dissection was done to remove the epididymis from the testes ^{8,9}.

Measuring dimension of testes

The lengths, breadth, height of the testes were measured using vernier caliper **Fig.1** and the volume of the testis were calculated using the Lambert's formula (Volume = Length x Breadth x Height x 0.71 cu.cm) and weight of testes was taken ¹⁰. The testes were fixed by gendre's fluid (Fixative) for 48 hrs. The relative weight of testes gonado-somatic index (GSI) were calculated with the help of following formula (GSI = Weight of testes in grams / Body Weight

in grams x 100) where weight of Testes (Absolute weight in gram) and body Weight (weight of rats on the 40th day in gm) ^{11, 12}. The data's were tabulated.

Semen analysis

The semen samples were there after collected from the cauda epididymis and was drawn into a white blood cell pipette and diluted to 1:10 with normal saline. Improved double Neubauer ruling Chamber was used for counting the spermatozoa ⁸. Smears were also prepared from the semen samples. The slides were stained by Papanicolaou stain **Fig.2** ¹². The morphological characteristic of the sperm cells in all the smears were observed under oil immersion (100 X). The following abnormalities were noticed both in the control and experimental groups as described headless tail, rudimentary tail, curved mid piece, curved tail, looped tail, bent mid piece, tailless head, and bent tail ^{8, 13}. The percentage of normal and abnormal sperm cells were tabulated for both control and experimental group, by counting 200 sperm cells per smear and three smear per rat. The data's were analyzed by Chi-Square test.

Hormone analysis

Serum was separated, from the blood sample. Testosterone hormone level was estimated using ELISA analyzer and the readings were noted down.

Histomorphometry of testes

The Gendre's fluid fixed testes were embedded in paraffin wax by the routine histotechnique procedure ^{14, 15}. Eight sections (5 µm thick) were taken at different levels in each half of testis using rotary microtome and stained by haematoxylin and eosin ¹⁴. The stained slides were mounted and carefully observed for histological changes and morphometric analysis was done. Micrometry was used to measure the diameter of the seminiferous tubules. The stained slides were focused using 10x objective, about 50 tubules were counted in each section

and the diameter was calculated using the formula (Diameter of seminiferous tubules = Maximum length + maximum breadth / 2 C.µm)^{16, 17, 18}. The mean diameter was taken from the 50 seminiferous tubules per section of testes. The final average diameter of the seminiferous tubules of each animal was tabulated. The mean, standard deviation, Standard error mean were calculated and tabulated. Further the data's were analyzed by student's t test using Graph pad software quick calcs online calculator for scientist.

RESULTS

The mean weight of albino rats, volume and weight of testes, gonadosomatic index, sperm count, testosterone hormone level and diameter of seminiferous tubules were tabulated for control and experimental rats separately (**Table 1 and Table 2**) and analyzed by student's t test to prove that the data's are statistically significant.

DISCUSSION

The study shows the steroidogenic activity on weight of the experimental rats. The experiment animal shows a marked increase in testosterone hormone. The anabolic effect

induces an increase in the body weight of the animal. The initial weights of all the animals were noted down on day 1. After a period of 40 days, the mean body weight of experimental rat's 228±1.88 gm was found to be increased, when compared to control 181.17±1.9 gm **Table 1**. As the data were analyzed by student's t test, the P value was found to be highly significant on day 40 (0.0001) this was due to the anabolic effect of *Lonidium suffruticosum* administered. The histological analysis of testes showed a significant hypertrophy and increase in size of seminiferous tubules which resulted in increase of weight of the gonads **Fig 4 & 6**. The mean volume and the weight of control and experimental rats were compared, and found to be increased in experimental (1.31±0.126 cu.cm and 1.11±0.03 gm) when correlated with the control 0.83±0.05 cu.cm and 0.95±0.01 gm **Table 1**. The reason for increase is due to an elevated testosterone level which in turn increases the diameter of the seminiferous tubules that induces spermatogenesis resulting in an increase in sperm count [19]. The p value was 0.0001 highly significant for weight of testes and 0.0003 for volume which is also significant.

Table 1 Weight of animals, Volume and Weight of testes and Gonado somatic index:

Statistical analysis (n=10)	Weight of animals gm		Volume of Testes cu.cm		Weight of Testes gm		Gonado Somatic Index	
	C	E	C	E	C	E	C	E
Mean± SEM	181.17±1.90	228±1.88	0.83±0.05	1.31±0.126	0.95±0.01	1.11±0.03	0.48±0.01	0.52±0.01
SD	4.67	4.60	0.133	0.310	0.04	0.07	0.02	0.045
P – Value	< 0.0001		< 0.0003		< 0.0001		< 0.0193	

Table 2 Sperm count, Testosterone hormone level and Diameter of seminiferous tubules:

Statistical analysis (n=10)	Sperm Count Millions/ml		Testosterone hormone level (ng/ml)		Diameter of seminiferous Tubule(μm)	
	C	E	C	E	C	E
Mean± SEM	30.9 ±0.40	58.38±0.97	2.26±0.05	5.83±0.19	258.62±3.22	299.71±6.38
SD	1.001	2.381	0.119	0.47	7.9	15.64
P - Value	< 0.0001		< 0.0001		< 0.0001	

C – Control, E – Experimental, SE – Standard error Mean, SD – Standard deviation

Gonado Somatic Index (GSI) was taken as one of the parameters to correlate the increase in body weight and gonadal weight of the rats ^{11, 12}. The same parameter was utilized in this study to find the effects of drug. The GSI of experimental (0.52± 0.01) when compared to control (0.48±0.02) was less **Table 1**. The statistical P value of GSI (0.0193) which was significant as the weight of the animal and weight of the gonads are directly proportional to each other.

Mitra et al reported that the count was 55.33±2.47 millions/ml in single cauda epididymis of albino rats using phosphate buffer as a diluting fluid and the experimental animal showed increased counts up to 81.50±2.70 millions/ml ¹⁹. The present study came up with a mean sperm count of 30.87±0.41 millions/ml in control and 58.4±0.9 millions/ml in experimental **Table 2** which has brought out a marked increase in count, due to the effect of testosterone on sperm count via., the influence on spermatogenesis. The data analysis showed a P value of 0.0001 which is proven to be highly significant.

Oyeyemi et al studied the morphology of spermatozoa and categorized the abnormal and normal spermatozoa ⁸. Sperm cell morphology also includes primary and secondary

abnormalities, according to the classification by Noarkes et al. In this study about 8% of abnormal spermatozoa were found in control, whereas a much less 2.9% in experimental group thus producing good quality of sperm and the data's analyzed by Chi-Square test proved to be extremely significant (0.0001).

The testosterone level in *Lonidium suffruticosum* treated animal (5.83±0.19 ng/ml) which was less in control (2.26±0.04 ng/ml) **Table 2** and the effect was due to the alkaloids acting on ley dig cells to secrete more testosterone ²⁰. The statistical analysis showed p value 0.0001 which was significant.

Experimental rats showed pronounced hypertrophy of seminiferous tubules in testes. The interstitial tissues had been reduced to a small extent, while the tubular volume was much increased among experimental **Fig 4 & 6** but less in control **Fig 3 & 5**. The drug induced the spermatogenesis without causing any damage to the seminiferous tubules. The spermatozoa completely filled the lumen of seminal tubules of experimental (80-87%); the remaining tubules are either empty or filled with few scattered spermatozoa when correlated with control (54-60%) were filled with sperm cells or the remaining was found to

be empty, whereas other tubules had unequally distributed few spermatozoa **Fig 4 & 6**.

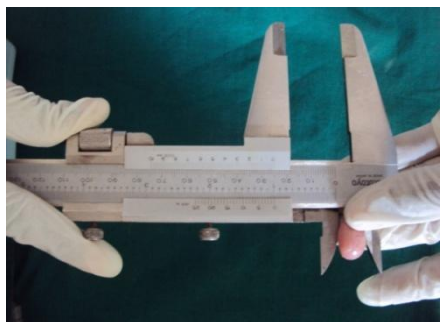

Fig 1 Measuring Testis

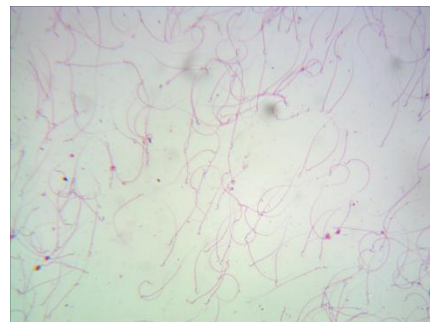

Fig 2 Semen smear (Papanicolaue stain)

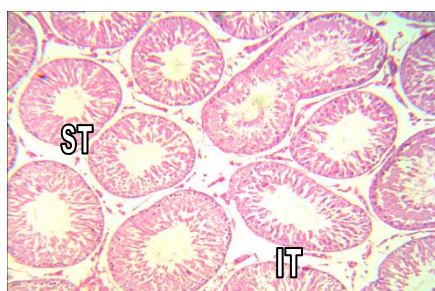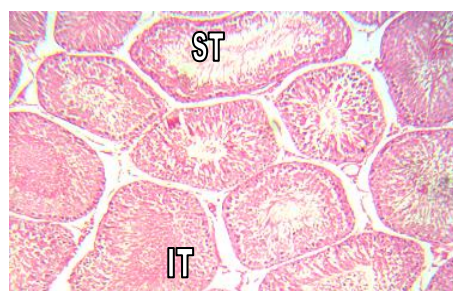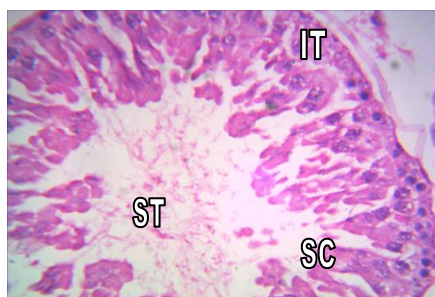


Fig 3. Control Rat testis



**Fig 4. Experimental Rat testis
(IT Moved out of the tube)**

Histological analysis - young rat testis low magnification 10 X (Same level section)



**Fig 5. Control Rat testis
(IT Moved out of the tube)**

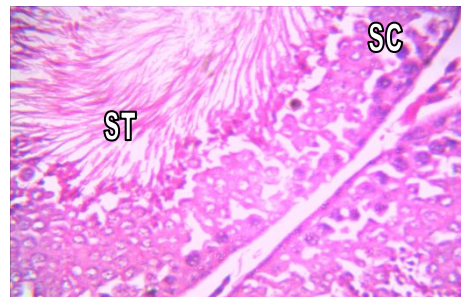


Fig 6. Experimental Rat testis

Histological analysis - young rat testis high magnification 40 X (Same level section)

ST-Seminiferous tubule, IT-Interstitial tissues, SC-Sertoli cells, LC- Leydig cells

The mean diameter of the tubules was charted out and found to be $258.62 \pm 3.22 \mu\text{m}$ in control, with a difference of forties in experimental $299.71 \pm 6.38 \mu\text{m}$ **Table 2** and when further analyzed by student's t test, showed a much significant P value of 0.001.

CONCLUSION

As globally herbs are gaining more importance in the treatment modalities of various conditions, recent researches are focusing more on herbal trials. The *Lonidium suffruticosum* were the corner stone of this study, the administration of which have shown significant positive results in improving various parameters

involved in maintaining maleness. This study involved young albino rats subjected to *lonidium suffruticosum* and the various parameters were analyzed which proved to be more effective in young rats. This study has given us a definite hope about the efficacy of the drug. The alkaloid specificity of the drug has to be further studied with more parameters with the aids of advanced technology. The study done in animal if extended in humans and if found to be equally effective; will turn out to be a boon for couples who were anxious to conceive.

REFERENCES

1. Javeed Ahmed Wani., Rajeshwara N, and Nema RK. Phytochemical screening and aphrodisiac activity of *Asparagus racemosus*: International journal of Pharmaceutical sciences and Drug research, 3(2): 112-115, (2011).
2. Badami S., Desai VB., Suresh P. Drugs play a major role in male infertility. Express Pharma Pulse , 2: 18 ,(2000).
3. World Health Organization, Biennial Report, Prevention of infertility, edt. J.Khanna, Office of Publication, W.H.O, Geneva, 1992-93, 32-33, pp. 161-166.
4. Kulkarni SK., Reddy DS. Pharmacotherapy of Male Erectile Dysfunction with Sildenafil. Ind. J. Pharmacol , 30: 367-378, (1998) .
5. Herbal powers – Nature’s best remedies [online] [cited 2009 dec 10]; Available from http://herbal-powers.com/ionidium_suffruticosum1.html
6. Ufaw., The Handbook on the management of laboratory animals. Churchillivingstone Edinburgh, London, 1976. pp.46.
7. Paul Flecknell., Laboratory animal anesthesia, 3 rd edn, Elsevier publication, 2009. pp.187.
8. Oyeyemi M.O., oluwatoyin O, AjalaLeigh O.O., Adesiji T., Fisayo. The Spermogram of male Wister rats treated with aqueous leaf extract of veronica amygdalina: Folia Veterinaria , 52(2): 98-101, (2008).
9. Gay I.W., Methods of animal experimentation, Academic Press, London, 1966. pp.54.
10. Ming Li Hsieh., Shih Tsung Huang., Hsin Chieh Huang., Yu Chen and Yu-Chao Hsu. The reliability of ultrasonographic measurements for testicular volume assessment: comparison of three common formulas with true testicular volume. Asian Journal of Andrology , 11: 261–265, (2009).
11. Qamar Hamid, LiagatAliminhas., Sadaf Hamid., Anjuman Gal. Influence of cimetidine and bromocriptine on weight of rats and its relation with fertility. Journal of clinical medicine and research, 2(2): 015-021, (2010).
12. RabiaLatif, Ghulam Mustafa Lodhi, Muhammad Aslam. Effects of amlodipine on serum testosterone, testicular weight and Gonado-Somatic Index in adult rats. J Ayubcollabhottabad , 20(4): 8-10, (2008).
13. Adebowale Bernard Saba, olayinka AO, Mathew Olubenga Oyeyemi. Spermatozoa Morphology and characteristics of male Wister rats administered with ethanolic extract of Lagenariabreviflora. African journal of Biotechnology 8(7): 1170-1175, (2009).
14. Druby R.A.B., Wallington E.A., Carleton’s Histological technique, 5th edn, Oxford University press, Newyork, 1980. pp. 140-142, 344-346.
15. Culling C.F.A., Handbook of Histopathological and Histochemical techniques, 3 rd edn, 1975, pp.49, 213, 491-92.
16. Tung Yang Wing., Kent Christensen., A Morphometric studies on rat seminiferous tubule. The American Journal of Anatomy, 165: 13-25 (1982).
17. Weibel E.R., Bolender R.P., Stereological techniques for microscopy. A Hayat Ed van Nostrand Reinhold, New York: pp.237-296.
18. Elias H, Hyde DM. An elementary introduction to stereology (quantitive microscopy). Am J Anat, 159: 411- 446,(1980).
19. Mitra SK, Muralidhar TS, Rao DRB. Experimental assessment of relative efficacy of drugs of herbal origin on sexual performance and Hormone levels in alcohol exposed and Normal rats. Phytotherapy Research,10: 296-299 (1996).
20. Patki PS. The role of indigenous drugs in the management of male sexual disorders. Probe (XXVIII): 25-28,(1988).



***Corresponding Author:**

Dr. B. Senthil Kumar
Research Scholar - Saveetha University
Tutor, Department of Anatomy,
Vinayaka Mission's Kirupananda Variyar Medical College and Hospital,
Salem – 636308.
Email – [skdrchinu88 @ gmail.com](mailto:skdrchinu88@gmail.com), [chinus.kumar9 @ gmail.com](mailto:chinus.kumar9@gmail.com)
Telephone number – 09894398677,08489793038